

See discussions, stats, and author profiles for this publication at: <https://www.researchgate.net/publication/349989364>

# MANAGEMENT OF SEVERE HEPATIC COCCIDIOSIS IN DOMESTIC RABBITS

Article · March 2021

---

CITATIONS

3

---

READS

248

2 authors:



**Bibin Becha**

Kerala Veterinary and Animal Sciences University

55 PUBLICATIONS 48 CITATIONS

SEE PROFILE



**Devi S. S**

Kerala Veterinary and Animal Sciences University

44 PUBLICATIONS 59 CITATIONS

SEE PROFILE

# MANAGEMENT OF SEVERE HEPATIC COCCIDIOSIS IN DOMESTIC RABBITS

**B. Bibin Becha\* and S.S. Devi**

Avian Disease Diagnostic Laboratory, Manjadi, P.O., Thiruvalla, Kerala – 689 105

Received : 28.11.2013

Accepted : 06.12.2013

## ABSTRACT

*High mortality in a period of one month due to hepatic coccidiosis was reported in a rabbit farm. Typical nodular lesions in liver and unsporulated oocysts of *E. stiedai* could be detected. Animals were treated with sulphamonomethoxime and diaveridine for five days followed by repetition of treatment after five days. Strict sanitary measures and disinfection of cages by spraying with 10 per cent ammonia solution was adopted. All animals with poor body conditions were removed from the flock and the disease was controlled.*

**Key words:** Hepatic coccidiosis, Rabbits, *Eimeria stiedai*, Kerala

## INTRODUCTION

Rabbit farming is emerging as a profitable venture in livestock enterprise in many parts of temperate and subtropical areas of India. Coccidiosis is a major problem in rabbit industry, seriously impairing their growth performance and causing high mortality rates during and immediately after rainy seasons. Usually adult rabbits act as symptomless carriers. Among the various species of *Eimeria* that infects rabbits, only *Eimeria stiedai* parasitises bile duct epithelium, leading to hepatic coccidiosis and are extremely

pathogenic. Studies on rabbit coccidiosis in Kerala showed a fairly high incidence of intestinal coccidiosis (Pillai and Subramanian, 1993; Shameem and Devada, 2005). This article places on record the high mortality among rabbits due to severe hepatic coccidiosis in a rabbit farm in Kerala and its therapeutic management.

## MATERIALS AND METHODS

Study was conducted in a rabbit farm in Kerala where a mortality rate of more than 50 per cent was reported. Clinical history and

---

\* Corresponding Author E.mail : bibinbecha@gmail.com

gross lesions were recorded during detailed post-mortem examination of dead rabbits. Liver was examined for typical nodules characteristic of hepatic coccidiosis. Impression smears were collected from cut surfaces of liver through the nodules and examined under high power objective of the microscope. Oocyst characteristics and micrometric studies of representative samples were conducted.

All the rabbits were treated with a combination of sulphaquinoxaline and diaveridine (Rancox powder) at the rate of 1g/litre of drinking water for 5 days, repeating the treatment after 5 days.

Strict sanitary measures were followed by cleaning the pens and utensils thrice daily. Bottom of wire cages were cleaned, brushed with a wire brush and dried daily. For disinfection of cages, 10 per cent ammonia solution was sprayed after cleaning. Culling and removal of poor body conditioned animals were adopted.

## RESULTS AND DISCUSSION

Mortality rate of over 50 per cent in a period of one month was reported in the rabbit farm. Diarrhoea, progressive emaciation and more death among young stock were reported. On necropsy, serous exudate was seen in the abdominal cavity. Liver was enlarged and congested with discrete to coalescing, irregular shaped yellowish nodules of 2–6mm diameter throughout the hepatic parenchyma (Fig. 1). Cut sections of liver showed yellowish white cheesy contents within the nodules. Impression smears from cut surface of liver showed large

number of unsporulated oocysts of *E. stiedai* (Fig. 2). Oocysts were ovoid in shape, pale yellow in colour and measured 34 × 20µm in size with a flat micropyle. Hepatic coccidiosis in rabbits has been reported from different parts of the country like Karnataka (D'Souza et al., 1992), Himachal Pradesh (Jithendran and Bhat, 1995), Meghalaya (Rajkhova, 1996), Kashmir valley (Magrav et al., 2010) Kerala, (Lakshmanan et al., 2011) and Tamil Nadu (Palanivel et al., 2013).

The animals responded to treatment with sulphaquinoxaline and diaveridine. All the emaciated and disease suspected animals were culled and removed from the flock. Proper medication and strict hygienic and sanitary measures adopted in the farm could control hepatic coccidiosis.

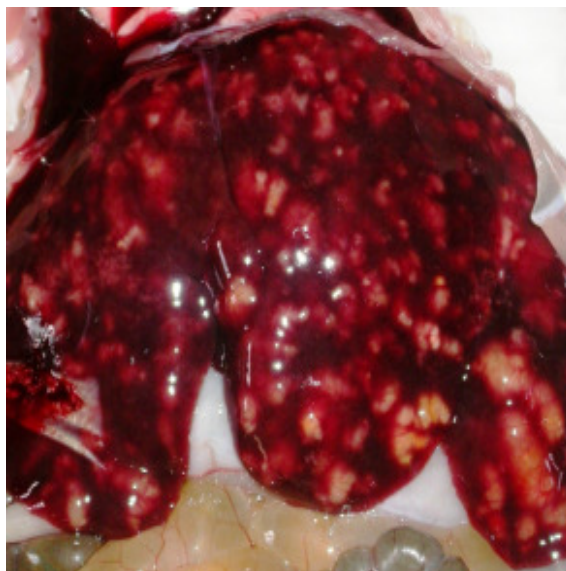
Bautista et al. (1987) reported that the clinical effects of hepatic coccidiosis are more severe in young ones and resistance develops as age advances. Adults remain as carriers and are a potential threat to the susceptible young ones. Infection with *E. stiedai* in rabbits is economically more important since it reduces the carcass weight by more than 23 per cent (Barriga and Arnoni, 1981).

Successful treatment of rabbit coccidiosis using sulphaquinoxaline was reported (Laha et al., 1999 and Magray et al., 2010). Singla et al., (2000) reported that toltrazuril at the rate of 25 ppm for two days in drinking water was highly effective for treating clinical outbreaks of hepatic coccidiosis in rabbits. Extracts of *Commiphora molmol*, such

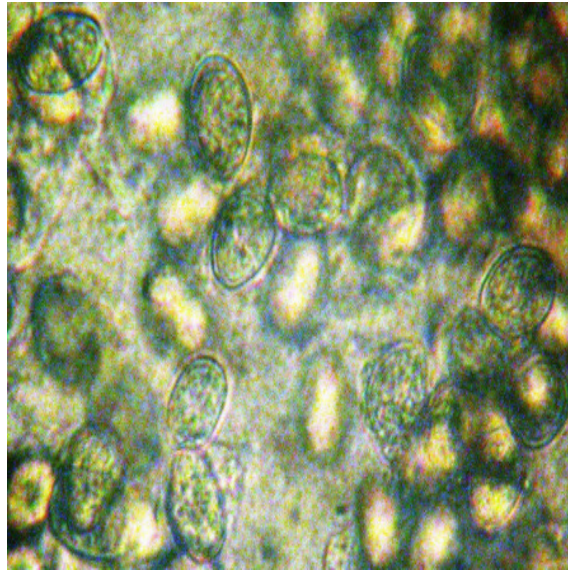
as mirazid, are promising sources for novel effective anti-coccidial drugs that are safe to the animal and environment (Al-Mathal, 2010). Oral administration of crude garlic ameliorated the adverse impacts of hepatic coccidiosis in rabbits when used as a prophylactic drug, but was less effective as a therapeutic agent (Abu-Akkada et al., 2010).

Hygienic maintenance of rabbitry plays an important role in control of rabbit coccidiosis. When oocysts are removed from the rabbit facility sooner than they finish sporulation prevents coccidiosis by significant reduction of infective doses of oocyst. Moreover, daily infection with small doses of oocyst is the best way to obtain an important degree of immunity (Pakandl, 2009).

**Fig. 1 Yellowish white nodules in liver**



**Fig. 2 Unsporulated oocysts of *Eimeria stiedai* in liver impression smear**



#### REFERENCES

- Abu-Akkada, S.S., Oda, S.S. and Ashmawy, K.I. (2010). Garlic and hepatic coccidiosis: Prophylaxis or treatment? *Tropical Animal Health Production*, **42**(7): 1337 – 1343.
- Al-Mathal, E.M. (2010). Efficacy of *Commiphora molmol* against hepatic coccidiosis (*Eimeria stiedai*) in domestic rabbit. *Journal of Food, Agriculture and Environment*, **8**(3&4): 1072 – 1080.
- Barriga, O.O. and Arnoni, J.V. (1981). Pathophysiology of hepatic coccidiosis in rabbits. *Veterinary Parasitology*, **8**: 201 – 210.
- Bautista, M.G., Vazquez, F.A. and Alunda, J.M. (1987). The effect of the host's age on the pathology of *Eimeria stiedai* infection in rabbit. *Veterinary Parasitology*, **24**: 47 – 57.
- D'Souza, P.E., Rajeshwari, Y.B., Jagannath, M.S. and Rahman, S.A. (1992). Coccidiosis in rabbits. *Livestock Advertising*, **17**: 26 – 28.
- Jithendran, K.P. and Bhat, T.K. (1995). Subclinical coccidiosis in Angora rabbits, a field survey in Himachal Pradesh. *World Rabbit Sciences*, **4**: 29 – 32.

- Laha, R., Hemaprasanth, D.A. and Harbola, P.C. (1999). Comparative efficacy of sulphadimidine and combination of amprolium, sulphaquinoxaline in the control of natural coccidial infection in rabbits. *Indian Veterinary Journal*, **76**: 1013 – 1015.
- Lakshmanan, B., Ravindran, R., Vasudeven, V.N. and Devada, K. (2011). Hepatic coccidiosis in rabbits in Kerala. *Journal of Indian Veterinary Association*, **9**(2): 56 – 57.
- Magray, A., Khan A.R. and Rashid, M. (2010). Study on fatal hepatic coccidiosis in rabbits of Kashmir Valley. *Journal of Environment and Bio Sciences*, **24**: 243 – 245.
- Pakandl, M. (2009). Coccidia of rabbit: a review. *Folia. Parasitologica*. **56**(3):153–166.
- Palanivel, K.M., Sureshkumar, K. and Rishikesavan, R. (2013). Prevalence of hepatic coccidiosis in rabbits – A post-mortem analysis. *Indian Veterinary Journal*, **90**(11): 72 – 73
- Pillai, K.M. and Subramanian, H. (1993). Intestinal coccidiosis of rabbits in Kerala. *Journal of Veterinary Animal Sciences*, **24**(2):190 – 191.
- Rajkhowa, C. (1996). Incidence of rabbit coccidiosis in Meghalaya and its control. *Journal of Veterinary Parasitology*, **10**:175 – 178.
- Shameem, H. and Devada, K. (2005). Prevalence of rabbit coccidiosis in Thrissur. *Journal of Veterinary Parasitology*, **19**(1): 69 – 70.
- Singla, L.D., Juyal, P.D. and Sandhu, B.S. (2000). Pathology and therapy in naturally *E. stiedai* infected rabbits. *Journal of Protozoology Research*, **10**: 185 – 191.