



MediRabbit.com

Hairlessness in rabbits is a rare occurrence...

Michel Gruaz and Esther van Praag

Occasionally an abnormality in the development of fur, called congenital hairlessness or hypotrichosis, is observed in rabbits. The anomaly seems independent of the rabbit breed. The color of the hair does not play a role either.

The first observations of rabbits suffering from an absence of fur are from the beginning of the 20th century in Russia and Great Britain. Other observations were made

later in France. Depending on the country, these rabbits had a decreased fur density and present variations in hair growth. This led to the conclusion that there are different



Figure 1: American white-tailed cottontail newborn with a form of congenital hairlessness. Photo:

mutations that cause either a partial or a generalized hair loss on the body (congenital hairlessness) or a reduced to no hair growth (hypotrichosis). Congenital hairlessness appears to be independent from the rabbit breed. It has been observed in Vienna whites, lop rabbits, Hyplus strain rabbits, Rex and Minirex rabbits, Belgian Bearded rabbits, and even in a wild American white-tailed cottontail (Figure 1). The development of hairlessness is usually symmetrical across the body, and is more frequently seen on the head, limbs, chest and abdomen. Only one or two individuals from a nest may be affected by this mutation, more rarely all newborn are affected (Figure 2). The other members of the litter have a normal fur growth by the age of one week. In rabbit breeds with several different types of hairs on the body, like Lionhead or Belgian bearded rabbits, regions devoid of one type of fur may appear (Figures 5, 6). Hairlessness may also develop later. A

newborn rabbit can develop a normal fur until a few weeks old, then, hairs fall *en masse* within a few days, leaving the skin bare and unprotected. If the newborn rabbit is healthy, without signs of disease or the presence of skin parasites, it is likely to have hypotrichosis or, in an extreme case, congenital hairlessness.

Genetics of congenital hairlessness

Different genetic mutations have been associated with congenital hairlessness or hypotrichosis in rabbits. These spontaneous mutations are the result of natural errors in biological processes; they are caused by the modification of a single recessive gene. This explains the rare occurrence of congenital hairlessness. The effect of these mutations becomes apparent when fur starts to grow on newborns. Different forms of hairlessness have been observed in rabbits:

- The naked / hairless mutation results in



Figure 2: Trois membres d'une même nichée de lapins tachetés souffrant d'alopecie congénitale généralisée aux Pays-Bas. Photo: Anonymous/MediRabbit



Figure 4: Fuzz, a furless mini lop-eared rabbit, the progenitor of a rare line of furless rabbits. Photo: Prof. S. D. Lukefahr

an almost complete hairlessness. Only a few guard hairs cover the skin, which presents a transformation of the superficial layers. The latter keratinize and become hard. It is the rarest form of congenital hairlessness. Interestingly, these nearly hairless rabbits tolerate summer temperatures well (Figure 3).

- One mutation observed in rabbits refers to wire. This is the "Wirehair" (Wh) mutation. It is partially recessive and, therefore, affected rabbits have a less severe hairlessness than in the previous mutation. These rabbits have guard hair, but no undercoat. The amount of hair varies from one individual to another; however, the fur density remains lower than that of a normal rabbit.
- The recessive Pelt-loss (pl) mutation leads to congenital hairlessness that is characterized by an abnormal thickening

of the skin. Hair follicles are present in the skin, but they are compressed by the keratinized skin. As a result, hairs cannot emerge from the follicles.

- The juvenile hairless mutation affects young rabbits a few weeks old. After they develop a normal fur, they begin to lose hair all over their body except the tail, the tips of the limbs, the ears and the nasal area. Some rabbits remain like this throughout their life. In others, the hair begins to grow again after a few weeks and no other health problems are noted. The cause of this condition remains mysterious.

In other animal species, up to 13 different mutations have been observed, which induce congenital hairlessness. It is, thus, not excluded that other mutations exist in rabbits, which have not yet been studied and described to date.

Mutation versus skin or hormonal disorders

A full examination of the rabbit is necessary to differentiate congenital hairlessness from more common causes of hair loss. A microscopic examination of the fur and hairs helps determine the growth phase of hair in order to assess the possible causes of hairlessness. This test also helps confirm skin abnormalities, such as an abnormal thickening and keratinization. A genetic analysis is sometimes carried out. It is rather for scientific interest more than diagnosis. It is also important to inspect the

hair shaft with a magnifying glass. A hair with a clean break is the result of excessive scratching associated with itchy skin. The presence of skin parasites, fur mite or scabies, fleas, lice, must be checked. A damaged hair is indicative of bacterial or fungal inflammation of the skin. Dietary deficiencies also affect the quality of the fur as well as its density. These include deficiencies of vitamin A, some B vitamins or of the minerals like zinc.

Congenital hairlessness is often symmetrical on the body when viewed from above. Symmetrical lesions on the body of

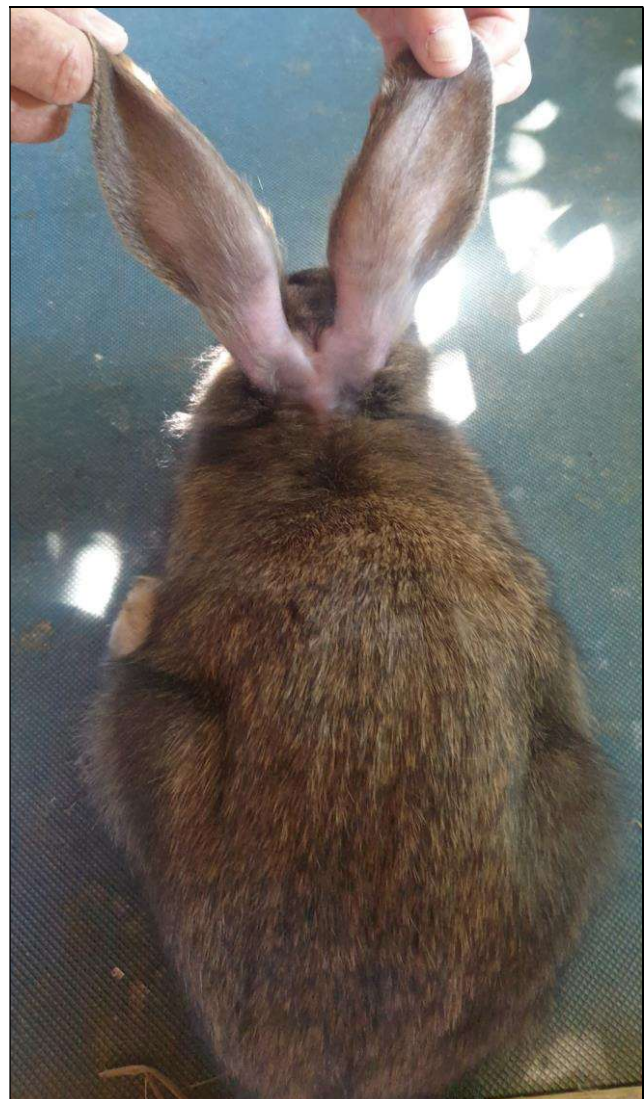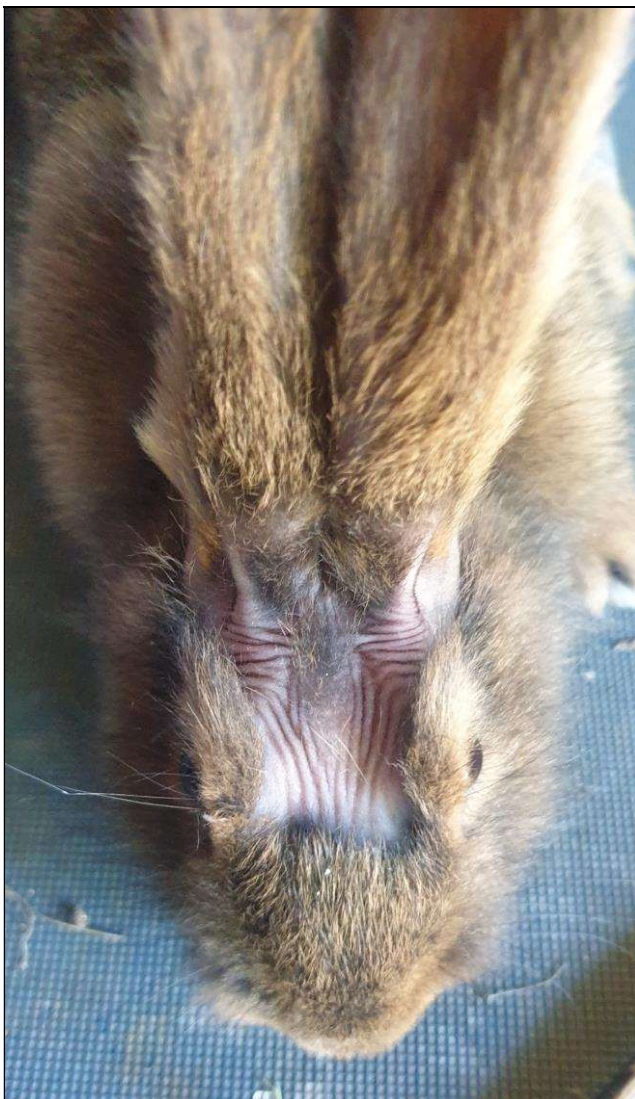


Figure 5: Young Belgian bearded rabbit affected by local hairlessness linked to one type of hair. When younger, it did not have fur on its limbs and tights. Photos: Michel Gruaz

the rabbit are, however, also associated with hormonal disorders, such as a disruption of sex hormones in male rabbits, thyroid dysfunction, also diagnosed in rabbits, or an abnormally high secretion of the stress hormone (cortisol) by tumors in the adrenal glands.

Microscopic analysis of the skin

Confirmation of congenital hairlessness is done under a microscope. Analysis of a skin sample taken from these rabbits showed thickening and excessive keratinization of

the skin. The emergence of new hairs is blocked, causing infections of the hair follicles. Excessive growth of the sebaceous glands is also observed, accompanied by an accumulation of sebum in the pores of the skin. Different health problems seem to be associated with congenital hairlessness. These rabbits seem to be slightly immunodeficient and are more often prone to skin disorders and bacterial diseases than normal rabbits. They are particularly susceptible to pneumocystosis, a lung infection caused by the parasitic fungus *Pneumocystis* sp.. Other abnormalities include damage to internal organs such as stomach wall ulceration, pyloric stenosis, cecal palsy, infertility and low reproduction rates. Life expectancy is very variable, ranging from 1 month for some individuals to several years up to the normal lifespan of a rabbit.

No treatment for the genetic defect

There is no treatment for rabbits with congenital hairlessness or hypotrichosis. In order not to spread this mutation among the offspring, these rabbits should be removed from breeding lines. They can, however, become perfect pet rabbits. Depending on the severity of the hairlessness, it is best to keep these rabbits indoors, in a protected and clean environment, and at comfortable temperatures. Indeed, without fur, they are sensitive to cold temperatures (some owners have knitted small sweaters for their furless rabbits), but also to biting insects such as mosquitoes.



Figure 6: Same rabbit as in Figure 5. The long hairs have started to grow on the head and flanks after several months. Photo: Michel Gruaz

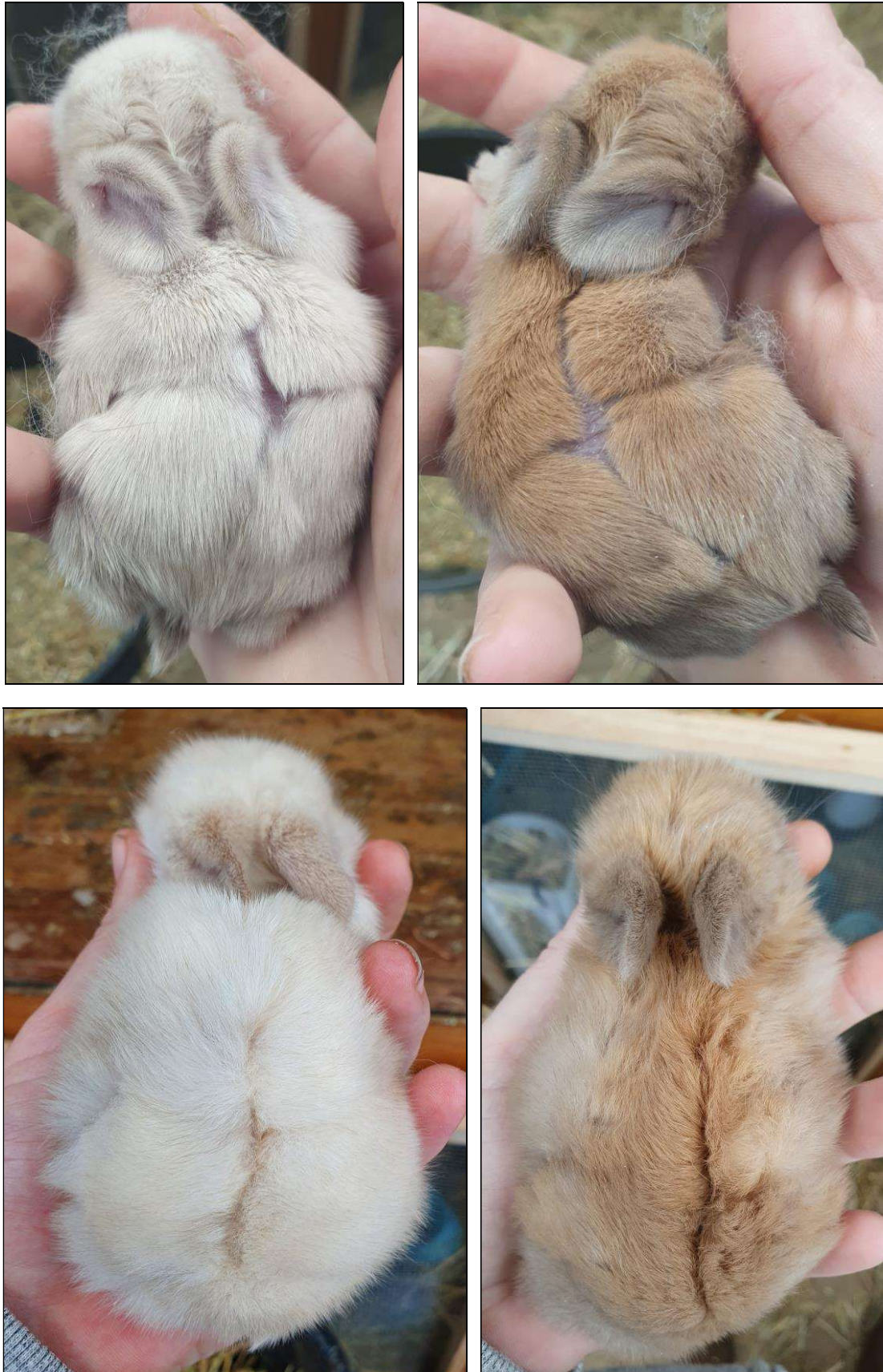


Figure 7: Congenital hairlessness ? Top: Two eight days old newborn of the same litter with alopecic marking over their spine and hips regions. In total 4 newborn of the same litter were affected. Bottom: same newborn at the age of 2 weeks. Photos: Stevie Wease

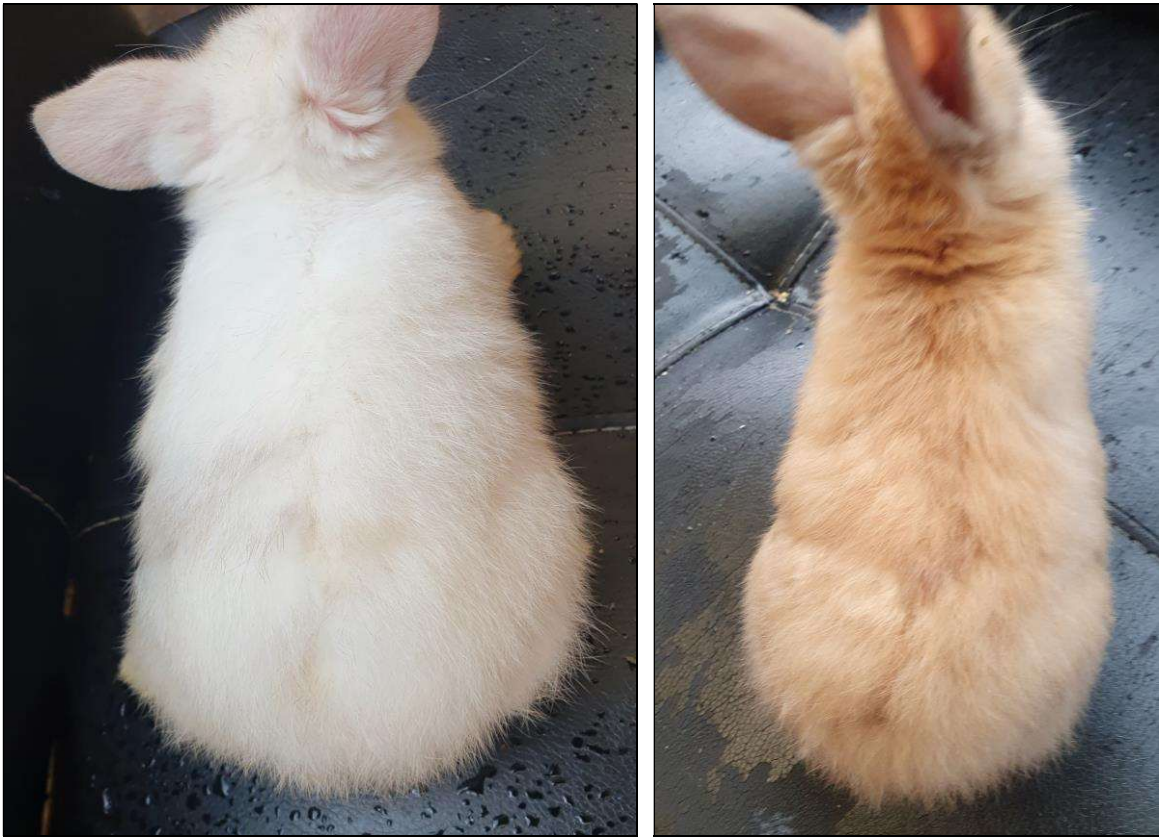

Figure 8: Same rabbits as in Figure 7, at 4 weeks and 6 days of age. Photos: Stevie Wease

They do, however, tolerate heat better than rabbits with normal fur. These rabbits also need to be protected from the sun's ultraviolet rays and sunburns due to the increased risk of developing skin tumors such as melanoma.

Acknowledgments

A big thank you to Prof. S.D. Lukefahr (USA), Christine Macey (USA), to the anonymous rabbit owner (The Netherlands), and to Stewie Wease (USA) for giving their photos for this article.

References

- Beynen AC, Mulder A, Nieuwenkamp AE, Van der Palen JGP, Van Rooijen GH. **Loose grass hay as a supplement to a pelleted diet reduces fur chewing in rabbits.** J Animal Physiol Anim Nutrition 1992;68:226-234.
- Boucher S, Nouaille L. Maladies des lapins. Paris, FR: Editions France Agricole; 2002.

Boucher S, Thebault G, Plassiat G, Vrillon JL, Rochambeau H. **Phenotypical description of hairless rabbits appeared in three different herds.** Congrès mondial de cyniculture, Toulouse, 1996.

Castle WE. The furless rabbit. J Heredity 1933;24:81-86.

East Drapeau E. **An anatomical study of the furless condition in rabbits.** J. Morphology 2005;54:365-388.

Florizoone K, van der Luer R, van den Ingh T. **Symmetrical alopecia, scaling and hepatitis in a rabbit.** Vet Dermatol 2007;18:161-164.

Gaman E, Fisher H, Feigenbaum AS. **An adequate purified diet for rabbits of all ages.** Nutritional Reports International 1970;1:35.

Geren, J, Chilson K, van Praag E. **Bilateral symmetrical alopecia is sporadically observed in male and female rabbits.** MediRabbit, 2017.

Jackson R, Rogers AD, Lukefahr SD. **Inheritance of the naked gene and associations with postweaning performance and thermotolerance characters in fryer rabbits from an F2 generation.** World Rabbit Sci 2006;14:147-155.

Kanai K, Nunoya T, Yasawa H, Shibuya K, Ihara M, Mizutani M, Yui F, Hoshi S, Tajima M. **Congenital hypotrichosis in Japanese White Strain (JW-NIBS) Rabbits.** J Toxicol Path 2000;13:21-27.

Kislovsky DA. **Naked - a recessive mutation in the rabbit.** J of Heredity 1928;19:438-439.

Lebas F. **Besoins nutritionnels des lapins: revue bibliographique et perspectives.** Cuni-Sci. 1989;5:1-28.

Rogers AD, Lupton CJ, Lukefahr SD. **Fiber production and properties in genetically furred and furless rabbits.** J Anim Sci 2006;84:2566-2574.