

## HEREDITARY ACHONDROPLASIA IN THE RABBIT

### I. PHYSICAL APPEARANCE AND GENERAL FEATURES

By WADE H. BROWN, M.D.,\* AND LOUISE PEARCE, M.D.

*(From the Department of Animal and Plant Pathology of The Rockefeller Institute for Medical Research, Princeton, New Jersey)*

PLATES 7 TO 12

(Received for publication, May 25, 1945)

Achondroplasia or chondrodystrophia foetalis is well known in man and certain other species, notably in cattle, dogs, and fowls, but it has not hitherto been reported in rodents. Recently, the abnormality in typical form has occurred in a rabbit breeding colony maintained for studies on constitution and the hereditary nature of the condition has been demonstrated. It is present at birth and is invariably lethal.

A considerable interest in achondroplasia has always been shown, principally because of the peculiarities of the bone development and also because of its apparently hereditary nature. The appearance of affected individuals is very striking. In human beings, the characteristic features include diminished size, shortened thick limbs, short broad hands and feet, an unshortened, usually straight, vertebral column, prominent abdomen, a large head with a prominent frontal eminence, a depression of the base or root of the nose, and a thickened wrinkled skin. Although the majority of cases are stillborn, or are non-viable, some survive and indeed adult achondroplastics are not extremely rare. In many respects, achondroplasia in dogs and in cattle resembles the human condition. Various suggestions have been made regarding the mechanism involved in the cartilage abnormality and the deficient bone formation consequent upon it and some investigators have thought that the endocrine glands, and the pituitary in particular, were directly implicated.

An hereditary basis for achondroplasia is now generally accepted. Recent studies of the human condition by Mörch (1) and Stephens (2) indicate that it is transmitted as a Mendelian dominant, and Mörch is of the opinion that it is a relatively frequent result of mutation. In the dog, Stockard (3) found that achondroplasia of the extremities is inherited as a simple Mendelian dominant. In cattle, two principal types or forms have been described. The well known "bull dog" calf of the Dexter breed, which was extensively studied by Crew (4), is inherited as a dominant or semidominant and is lethal in the homozygous state. The other form, in the Telemarck breed in

---

\* The untimely death of Dr. Brown on August 4, 1942, occurred during the early phases of the work on achondroplasia. The first cases occurred in certain rabbit stocks that he was studying and he immediately began breeding experiments for further investigation. He identified several transmitters and initiated the breeding of hybrid material for genetic studies. This group of papers is presented with the hope that they will reflect in some measure his lively interest in the many unique and significant features of the disease.—L. P.

Norway (5) and later encountered in other breeds elsewhere, is thought to be inherited as a single recessive (6-9). Recently, an achondroplastic sublethal defect in cattle that is somewhat variable in expression has been reported from California by Gregory, Mead, and Regan (10). The greatest modification appears in the development of the skull and jaws, and leg length is little affected. The condition is inherited as a monofactoral autosomal recessive.

That achondroplastic dwarfism of the rabbit is rare is indicated by the experience of this laboratory over a period of 14 years, during which large numbers of pure bred, hybrid, and mongrel stocks have been carefully followed from birth to death. No example of the condition other than those now reported has been seen. However, among new-born young, normally proportioned diminutive forms are encountered fairly frequently. Greene (11) has studied an hereditary type of dwarfism, present at birth, in a family of the Polish breed in this colony. In homozygous form, the variation is lethal and produces a miniature individual approximately one-third the size of its normal sibs; the bodily proportions, except for an abnormal skull shape, are uniformly reduced. The dwarf-like forms usually seen include those comparable to the runts of domestic animals, and the other forms have other distinguishing characteristics which are typical features of certain pathological complexes that are under investigation in this laboratory. Among the young of various ancestry, one occasionally sees a round or "bullet-headed" animal of normal or diminished size and there are others in which the extremities have seemed somewhat short. All these small forms are normally proportioned, however, and actually none of them could be confused with the very distinctive achondroplastic animal.

The observations on the cases of achondroplasia in rabbits and the results of breeding experiments have been divided into three categories for presentation. The physical appearance of the animals and various other evident features are described in the present paper. The pathological aspects of the condition are reported in a second paper (12). The third paper (13) contains an analysis of breeding tests carried out to determine the mode of inheritance, together with a discussion of the parent stocks of the original cases with respect to the possible influence certain factors carried in these lines might have had on the development of the condition. Certain aspects of the disease, with special reference to achondroplasia in other species, are also discussed.

#### *The First Cases of Achondroplasia*

Only a brief description of the first cases of achondroplasia will be given here as the subject is discussed in a subsequent paper (13).

The first instance of achondroplasia occurred in a litter of 5 animals derived from a cage mating of a young doe. The mother was a pure bred Havana and the father was thought almost certainly to be one of her two brothers which had been caged with her and with two other sisters. The litter contained 2 dead typical achondroplastic dwarfs and 3 living normal animals. Repeated attempts to duplicate the condition by various breeding experiments failed. Two years later, however, another litter containing typical cases was born.

The second litter contained 5 young, 3 living apparently normal animals and 2 dead achondroplastic dwarfs (Fig. 1). It should be pointed out that the condition of the doe during pregnancy and after littering was good, as is indicated by body weight determinations: 2850 gm. when mated, 3200 gm. on the 14th day of pregnancy, and 3050 gm. a few hours after littering. The mammary reaction was normal and there was a fine fur nest in the littering keg. The doe gave her own and a foster animal excellent care.

The second litter was the progeny of a backcross mating in stock of particular interest because of an inherited disease complex in which premature senescence is a prominent feature. This disease was originally observed in pure bred Belgian rabbits, but the present stock is mixed or mongrel as a result of various crosses. The male parent of the second litter represented an  $F_1$  generation of this complex; his father was a typical example of the adult form of the disease and his mother, the normal partner of the cross, was a pure bred Havana. This Havana female was also a great grandmother on the maternal side of this second litter. Furthermore, she was the grandmother of the first achondroplastic litter.

The third achondroplastic litter which was born while breeding tests with the father of the second litter and various related females were under way, made the Havana origin of the variation practically certain. This litter of 8 young comprised 3 dead achondroplastic dwarfs and 5 living normal animals. The doe showed no untoward symptoms during the pregnancy and her condition after littering was excellent. She and the father of the litter were brother and sister  $F_1$  hybrid animals, the progeny of a pure bred Dutch male and a pure bred Havana female who was a full sister of the mother of the first achondroplastic litter. The Dutch parent belonged to a stock which carries a peculiar disease complex characterized by a variety of symptoms including hydrocephalus, abnormal tooth and bone development, and deficient growth. The changes in the bones, however, are not those of achondroplasia.

The Havana grandmother of the third litter was in the colony at the time the litter was born as was also her half brother, the father of the second litter. The progeny derived from the breeding of these 2 animals contained 1 achondroplastic and 5 normal young. By this time, the Havana origin of the variation seemed assured. And, as will be described later (13), subsequent cases were obtained in pure bred animals of this stock by appropriate matings.

#### *Materials and Methods*

The achondroplastic stock was built up from surviving parents and members of the original litters just described. Certain transmitters were outcrossed to unrelated stock to form an  $F_1$  hybrid generation and further breeding tests with identified transmitters of this generation were carried out to determine the mode of inheritance. From these various sources, the material on which this study is based was obtained. It comprises 228 achondroplastic dwarfs contained in 132 litters.

A detailed description of affected individuals was included in the notes dictated at the time the litter was first examined, that is, within a few hours of birth. The animals were weighed on a Toledo automatic balance calibrated in gram intervals and their sex was recorded. A considerable number of dwarfs were x-rayed for further study, particularly for bone measurements. Postmortem examinations were carried out and representative tissue sections were studied microscopically. For comparative general and pathological purposes, new-born rabbits of various classes were employed, including normal litter mates and normal unrelated young, diminutive animals of various types, and animals born prematurely. Many of these control animals were killed by chloroform anesthesia but a number of new-born young found dead were also included.

The data obtained from certain observations have been analyzed. This material includes birth weight values used here as an index of size and a series of measurements of the following bones: humerus, radius, femur, tibia, the cervical, thoracic, and lumbar portions of the spine, and the anterior-posterior and transverse diameters of the skull.

All adult rabbits in the colony are housed in large individual cages, and the diet comprises a constant water supply, timothy and alfalfa hay, and a standard pellet preparation of the best quality obtainable. An excellent condition of health is maintained. In breeding experiments, the duration of pregnancy can be calculated to within a few hours. The time of most matings is exactly known and in those cases in which the doe is left with the male, it is known to within 18 hours.

#### RESULTS

Hereditary achondroplasia in the rabbit is characterized by two outstanding features, namely, a typical physical appearance and a uniformly lethal effect. The disease is incompatible with life. Of 228 cases all except 11 were dead when the litter was first examined a few hours after birth. Of the 11 animals found alive, 5 survived only a few minutes, and 4 for 6 hours, while 2 are known to have lived at least 12 hours.

The animals were well nourished and the general condition of the majority indicated that death had occurred at the time of or shortly after parturition. As a rule, the litters were born at term. With certain exceptions, the skin, toe nails, and the skeletal musculature were well developed, the nares were patent, and the incisor teeth were erupted. There were some instances of definite prematurity of some 24 to 48 hours' duration. The animals were usually well washed and there was only an occasional instance of attached fetal membranes and placenta.

The achondroplastic animals were the only members of the litter showing any gross abnormalities that could be attributed to the disease. There was nothing in the subsequent appearance of the normal sibs in youth or maturity to suggest the condition. Transmitters could be identified only by breeding tests. There were occasional animals, and these were among the smaller members of a litter, about which there was some uncertainty with regard to comparative leg length and head shape. In all these cases, however, x-ray examination showed normal proportions.

There was comparatively little variation in the general appearance of achondroplastic individuals. The outstanding features were reduced size, markedly shortened extremities, a broad short squarish head with prominent calvarium, a transverse depression across the base of the nose, small teeth, flat muzzle, a comparatively short and flaring thorax, a conspicuously large relaxed abdomen, and a short broad fleshy tail. There were also marked redundancy of the skin, a large fleshy protruding tongue, occasional folding of the ears, and in certain cases, a cleft palate. These general features will now be described.

*General Description*

*Size.*—A characteristic feature of the condition is a reduction in size, and in the great majority of cases, the achondroplastic animal was considerably smaller than the normal sibs (Figs. 1, 15, and 16). Comparisons of birth weights indicate the degree of size reduction (Table I).

TABLE I  
*Mean Birth Weight Values of Achondroplastic and Normal Rabbits*

No. of litters	Total births	Achondroplastic animals		Non-achondroplastic animals					
				Living					
		No.	Mean weight gm.	Total No.	Mean weight gm.	Normal		Diminutive	
						No.	Mean weight gm.	No.	Mean weight gm.
49 positive.....	286	82	33.7	204	53.3	189	54.0	5	26.5
73 negative.....	428			428	49.8	405	50.6	13	27.6

In 49 litters containing 82 achondroplastic and 194 living and 10 dead non-achondroplastic young, the mean birth weights were 33.7 and 53.3 gm. respectively; the value for the achondroplastic animals is 63.2 per cent of the mean value for the normals. A slightly smaller but comparable mean birth weight for normal young of this stock was found in the results on a group of 73 negative litters in which there were no cases of achondroplasia; the mean weight value for 428 animals was 49.8 gm.

The frequency distribution of the various weight classes of achondroplastic animals has been compared with those of their normal sibs and the animals of the negative litters just referred to (Chart 1).

The curves representing the 2 groups of normal animals approach a normal frequency curve, and are in fair agreement, although the one representing the normal sibs is more irregular and there is one striking divergence at the 50 to 54 gm. level. The numerical disparity of the two groups, 204 normal sibs and 428 young in the negative litters, may account for these differences.

The curve representing the achondroplastic young differs radically from those of the 2 normal groups. It will be noted first that the position of the curve shows that the great majority of achondroplastic animals had much smaller birth weights than the majority of the normal animals.

As a matter of fact, 86.7 per cent of the achondroplastic animals had birth weights not exceeding 39 gm. as compared with 15.9 and 21.2 per cent respectively of the normal sibs and the young of the negative litters. Second, the shape of the curve illustrates in a striking fashion the fact that the weight values for approximately three-fourths of the cases, 72.0 per cent, lie within the comparatively narrow range of 30 to 39 gm. The remainder of the animals were almost equally divided between values just above and below this narrow range, 14.7 per cent in the smaller weight classes of 20 to 29 gm. as compared with 13.4 per cent in the 40 to 54 gm. classes.

A comparison has also been made of the relationship of the weight of each individual in a litter expressed in terms of a percentage of the weight of the heaviest litter mate. This procedure eliminates the variation due to differences in the absolute weights of animals of different litters, since all observations

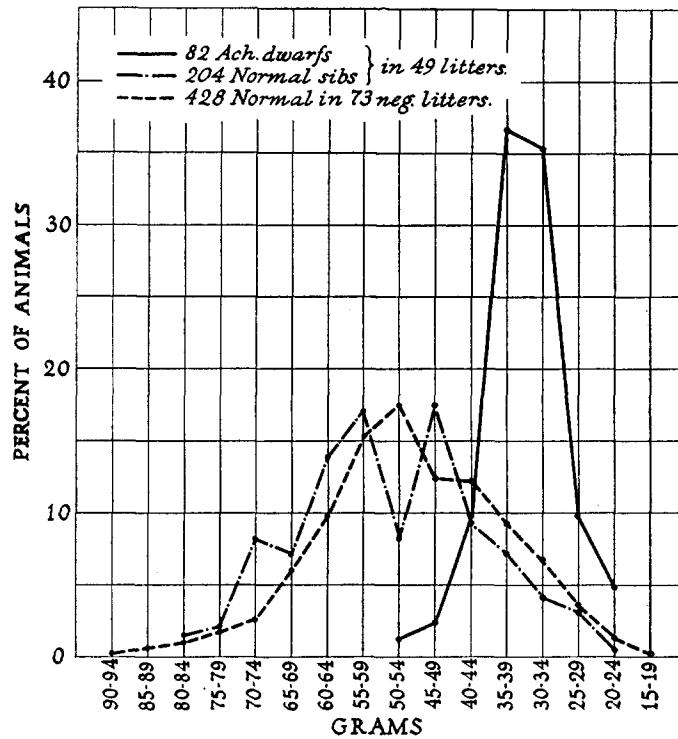


CHART 1

are given a relative value (14). The percentage values were grouped in classes in descending order of magnitude and the frequencies in each class are shown in Chart 2.

It will be noted that in the case of the 2 groups of normal animals, the frequencies describe a fairly orderly decrease from the highest number in the 100 to 95.1 per cent class to the lowest in the 40 to 35.1 and 45.0 to 40.1 per cent classes respectively. The frequencies of the achondroplastic animals, on the other hand, have a markedly different distribution. In the heavier classes, from 95.0 to 90.1 per cent to 70.0 to 65.1 per cent, there were only a few animals and although the curve is almost a straight line, there is a slight upward trend which becomes more pronounced at the 65.0 to 60.1 per cent level. The majority of the animals, that is 53 of 82 or 64.6 per cent, were in the three classes from 60.0 to 45.1 per cent as shown by the sustained height of the curve, which is in sharp contrast to the continued fall of the curves of the normal

young. In these 3 weight classes, there were only 9, or 4.5 per cent, of the normal sibs. There was a small representation of achondroplastic animals in the 2 lowest classes and here the downward direction of the curve corresponds to those of the normal animals.

A further comparison has been made in which the relationship of the weight of each individual is likewise expressed in terms of a percentage of the weight of the heaviest sib, but in this case the frequencies in each class are expressed in relative or percentage values of the total number of animals (Chart 3). On this basis, the marked variations in the weight distribution frequencies of the

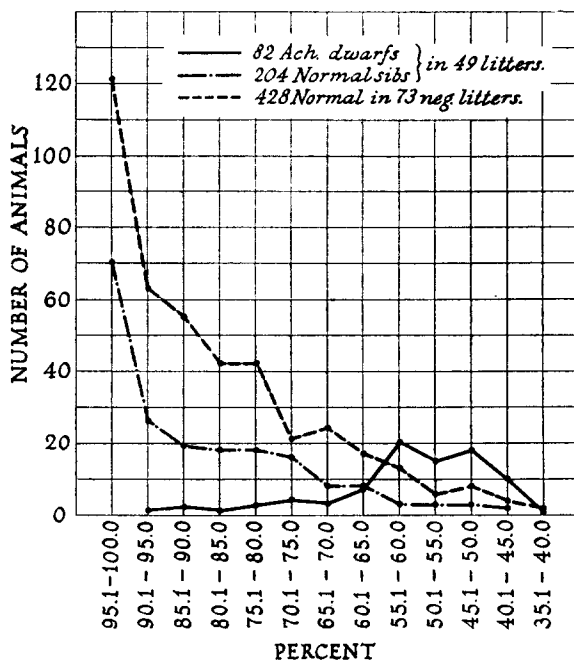


CHART 2

achondroplastic animals as compared with those of the normal young are very strikingly shown. The curve representing the achondroplastic young is again significantly different both in position and shape from those of the 2 normal groups which are very similar. The curves show very clearly that the great majority of the achondroplastic animals, but only a small proportion of the normal ones, had birth weights ranging from 45.1 to 60.0 per cent of the heaviest sib.

The occurrence of diminutive, normally proportioned forms in the rabbit has been mentioned. In the positive litter group, there were 5 and in the negative litter group there were 13 non-achondroplastic diminutive living animals whose birth weights ranged from 17 to 41 gm. with mean values of 26.5 and 27.6 gm. (Table I). Their incidence rates were 2.5 and 3.04 per cent respectively. In relative terms, the range of weight values was 38.6 to 50.0 per cent of

the weight of the heaviest sib. In the next heaviest classes, from 50.1 to 65.0 per cent, there were 14 animals in each litter group, an incidence of 6.9 and 3.4 per cent respectively of the non-achondroplastic young. The birth weights ranged from 25 to 53 gm. with mean values of 35.6 and 29.6 gm. respectively for the 2 litter groups.

These normally proportioned diminutive animals belonged to several different types, chiefly the hereditary form found in certain Belgian stock of this colony and known by the colloquial

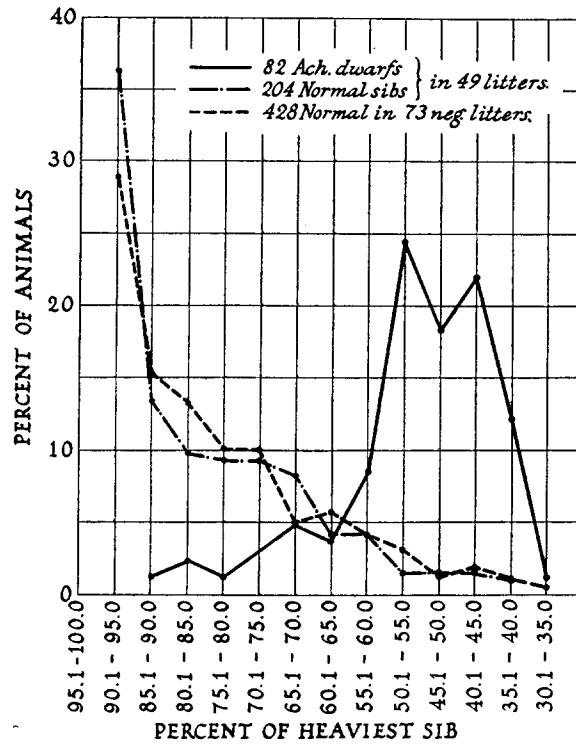


CHART 3

name of Downy-Rusty-Dwarf and second, the hereditary forms characteristic of a family of Polish rabbits (11). Both types occurred more frequently in earlier than in later litters, for many of the early ones contained a concentration of the Belgian blood while representatives of the Polish family were used for some of the first outcross matings. The family of the Havana breed also represented in the achondroplastic stock is known to carry a diminutive factor and there were one or two of these forms in the group. Finally, it will be remembered that non-hereditary small forms may occur. The inclusion of the birth weights of these various diminutive animals affects only slightly the mean group values.

*Extremities.*—A pronounced shortening of the extremities is a characteristic feature of all cases and it is, perhaps, the chief abnormality most responsible for the bizarre appearance of the animal (Figs. 1 to 6, 15 to 17). The legs are straight; there is no suggestion of twisting or bowing. Both segments of the



TABLE II

*Comparison of Mean Bone Lengths of Achondroplastic Dwarfs and Normal Sibs*

Group I—10 litters—43 normal sibs—14 achondroplastic dwarfs.

Group II—12 litters—23 normal sibs—25 achondroplastic dwarfs.

Bone	Litter group	Mean bone length				Mean of individual litter differences
		Normal sibs	Achondroplastic dwarfs	Difference		
		<i>mm.</i>	<i>mm.</i>	<i>mm.</i>	<i>per cent</i>	
Humerus	I	12.6	4.7	-7.9	-62.7	-62.3
	II	12.7	5.2	-7.5	-59.1	-58.9
Radius	I	10.8	3.8	-7.0	-64.8	-63.9
	II	10.8	4.4	-6.4	-59.3	-57.0
Femur	I	11.3	4.4	-6.9	-61.1	-61.5
	II	11.5	4.6	-6.9	-60.0	-59.4
Tibia	I	14.0	6.0	-8.0	-57.1	-56.7
	II	14.3	6.6	-7.7	-53.8	-53.2
Cervical vertebrae	I	14.6	11.5	-3.1	-21.2	-21.1
	II	14.8	12.1	-2.7	-18.3	-18.2
Thoracic vertebrae	I	28.5	20.8	-7.7	-27.0	-27.0
	II	28.8	22.0	-6.8	-23.6	-23.0
Lumbar vertebrae	I	23.7	16.6	-7.1	-29.1	-30.1
	II	24.1	17.5	-6.6	-27.4	-26.6
Anteroposterior skull	I	27.8	22.3	-5.5	-19.8	-19.9
	II	28.9	23.4	-5.5	-19.4	-18.5
Transverse skull	I	16.7	16.4	-0.3	-1.8	-2.4
	II	16.8	17.3	+0.5	+3.0	+3.2

The figures in the last column represent the means of the percentage differences of individual litters. In this calculation, the mean bone lengths of the achondroplastic dwarfs and of the normal sibs of each litter were compared and the difference between them was expressed in the percentage of the mean value of the normals.

legs and the paws as well are affected as is shown in x-ray photographs (Figs. 7 to 11, 18 to 20).

The short appearance, particularly of the forelegs, is frequently heightened by the presence of conspicuous redundant skin folds in the shoulder girdle, upper thorax, and upper foreleg regions. These folds tend to bind the legs close to the chest wall with the result that a large portion of them is obscured (Figs. 2 to 5, and 16). A similar condition of the hind legs is also found (Figs.

2 to 5, 15 to 17) but in general, the folds are somewhat less pronounced than those in the anterior part of the body.

The extent or degree of shortening has been determined from a series of bone measurements made from x-ray photographs. The first group of 10 litters contained 14 achondroplastic dwarfs and the great majority of their normal sibs, namely, 43 animals. The second group of 12 litters contained 25 achondroplastic dwarfs and 23 normal young, that is, 1 or 2 representative normal sibs of each litter. The means of the several bone lengths are given in Table II and it will be noted that in the case of both classes of animals, the values of the 2 litter groups show a close similarity. The x-ray photographs reveal the marked deficiency in ossification of all bones.

The pronounced degree of shortening of the extremities is shown by the magnitude of the difference between the mean lengths of the abnormal and the normal bones expressed as a percentage of the normal value (Table II). For the humerus, radius, femur, and tibia, the shortening ranges from 53.8 to 64.8 per cent. Comparable results were obtained from a comparison based on the difference found in individual litters as shown in the last column of Table II; the mean values for the achondroplastic animals of each litter were compared with those of their normal sibs and the mean of these differences was then calculated.

An analysis has also been made of *relative* bone measurements, that is, measurements expressed in terms of a percentage of the net body weight, the latter value being obtained by subtracting the weight of the gastrointestinal tract from the actual body weight. The data of the 2 litter groups used in the preceding comparison were analyzed on the basis of the differences found in individual litters using the respective mean values of the achondroplastic animals and their normal sibs. The values shown in Table III represent the means of these individual litter differences.

TABLE III  
*Differences in Mean Relative Bone Lengths of Achondroplastic Dwarfs and Normal Sibs  
Expressed in Per Cents of the Normal Values*

Litter groups are the same as those of Table II.

Litter group	Fore leg		Hind leg		Vertebra			Skull	
	Humerus	Radius	Femur	Tibia	Cervical	Thoracic	Lumbar	Antero-posterior	Transverse
	<i>per cent</i>	<i>per cent</i>	<i>per cent</i>	<i>per cent</i>	<i>per cent</i>	<i>per cent</i>	<i>per cent</i>	<i>per cent</i>	<i>per cent</i>
I	-45.2	-45.0	-43.9	-36.7	+16.2	+3.4	+0.1	+17.6	+44.3
II	-43.7	-41.8	-44.5	-35.9	+17.2	-4.6	+6.3	+11.4	+43.2
Total.....	-44.4	-43.3	-43.8	-36.3	+16.0	-1.7	+3.1	+15.1	+43.8

It will be observed that the mean percentage shortening of the relative length of the humerus, radius, and ulna of the achondroplastic animals ranged

from 41.8 to 45.2 per cent of the corresponding value of the normal sibs. Slightly smaller values, 35.9 and 36.7 per cent, were found for the shortening of the tibia in the 2 litter groups. The combined results of the 2 groups, that is, for 39 achondroplastic and 66 normal sibs are graphically shown in Chart 4.

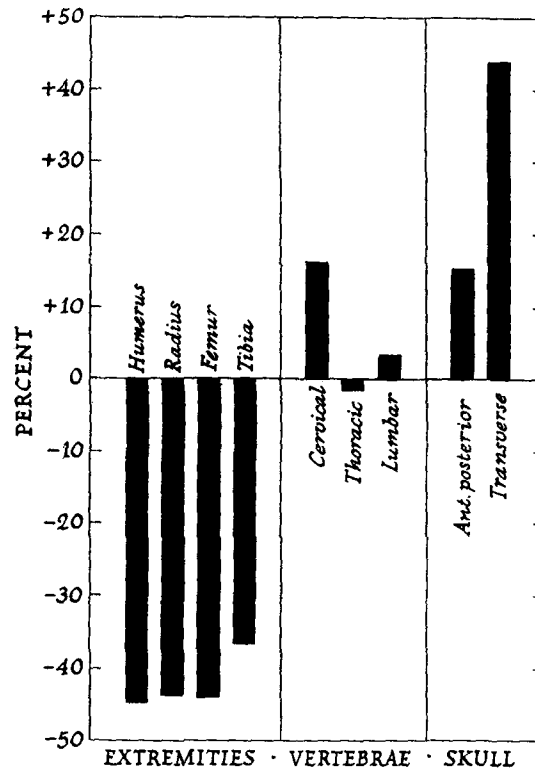


CHART 4. Deviations in mean bone measurements of 39 achondroplastic dwarfs from the corresponding values provided by 66 normal sibs. The results are expressed in per cents of the normal values which are represented by the transverse zero line.

The frequently unusual position of the legs and feet contributed to the peculiar appearance of the dwarfs. In normal young born dead or which die immediately after birth, there is commonly flexion of the elbow but little or none of the wrist and the palms usually point toward the tail (Fig. 5). In the achondroplastic young, the elbows were often flexed at right angles with the palms pointed ventrally in the so called "traffic" position (Fig. 2) or they faced each other or were in apposition with the chest wall (Fig. 4) while in still other cases, the paws were in the position of partial or complete wrist drop (Fig. 3). The binding skin folds already mentioned undoubtedly contributed to these unusual positions.

The position of the lower hind legs and feet showed less departure from the partial or almost complete extension found in normal animals (Fig. 5). However, there were many examples of marked flexion of knee and ankle joints (Fig. 4) and not infrequently the plantar surface of one or both feet pointed inward toward the midline (Figs. 4 to 6, and 16). Sometimes the ankle joint showed an obvious pronounced twist (Fig. 3). As in the case of the upper extremity, marked skin folds of the lower abdomen and thigh regions were associated with unusual leg and feet positions.

The feet appeared to be less affected than the legs as far as actual shortening was concerned but in the case of the hind feet, they frequently were thick, broad, and fleshy (Figs. 2 and 6). The redundancy of the skin, which might involve the lower leg segments and occasionally the feet, contributed to this spade-like appearance.

The toe divisions were generally well formed and the nails well developed, but there were 3 instances of partial web toes of the hind feet (Figs. 1 and 2). There were also 4 instances of absent or defective feet. There was 1 case in which all 4 feet were absent, the legs terminating in blunt ends at the wrists and ankles and in another, there was a similar deformity of the right hind leg. In the third case (Fig. 6), the right front leg terminated at the rounded stump of the radius and ulna; the left front foot was present but there were only 2 toes, the outer or fifth toe and an inner toe, probably the thumb, and both were rudimentary; the hind feet were normal. A fourth dwarf had a missing outer toe on the right front foot.

As far as could be determined, there was no restriction of motion in any of the joints of the extremities or of the spine. If any abnormality was present, it was in the direction of increased mobility.

*Head.*—In all cases, the appearance of the head was remarkable. Instead of an elongated and narrow or oval shape, it was squarish (Figs. 1, 5, 15, and 16). The vertical and transverse diameters were obviously increased while in comparison, the anterior-posterior diameter appeared to be shortened. The calvarium was prominent and frequently the posterior portion was protuberant (Figs. 3 and 5) suggesting hydrocephalus but this condition was found in only 2 cases. The face was short and broad with a retreating snub-nose muzzle of the chimpanzee type. Across the base or root of the nose was a transverse depression. It was present in all cases and although there was considerable variation in its area and particularly its depth, it was usually quite conspicuous (Figs. 3 and 5). The eyeballs were prominent. A contributing factor to the flatness of the face and muzzle was the prominence of the chin and lower jaw, in part brought about by the redundant condition of the skin and in some instances increased by edema of the skin and subcutaneous tissues (Fig. 4). The neck generally was broad and thick and the skin folds were frequently very pronounced (Figs. 2, 3, 16, and 17).

The characteristic shape of the achondroplastic skull is well shown in x-ray photographs. The profile views in Figs. 7 and 11 show the expansion of the

vault and the depression at the root of the nose. The rounded form of the base of the skull is illustrated in Figs. 12 and 21; the oval elliptical shape of the normal skull is shown in Figs. 13, 14, and 22.

The anteroposterior and transverse diameters of the skull were measured on the same x-ray photograph. There was no difficulty with the transverse measurement as the widest diameter was regularly selected. But, in the case of the anteroposterior diameter, it was soon found that the same anterior point of the skull proper could not be consistently identified and consequently, the nasal tip was chosen. This diameter, therefore, represents the length of the skull plus the length of the nose and is the longest anteroposterior measurement obtainable.

Analyses of the skull measurements were made in the same manner as those of the extremities and the results appear in Tables II and III and Chart 4. It will be noted that on the basis of actual measurements without taking into account the comparative size or weight of the animal, the mean anteroposterior diameter of the dwarf skull as compared with the mean value for the normal sibs was reduced by approximately 20.0 per cent in both litter groups (Table II). The transverse diameter was practically unaffected. When, however, the observations were analyzed on a relative basis, that is, in relation to the net body weight, it was found that both diameters of the achondroplastic skull were longer than those of their normal sibs (Table III). In the case of the anteroposterior diameter, the mean increase was 17.6 and 11.4 per cent respectively for the 2 litter groups while much larger values, namely 44.3 and 43.2 per cent respectively, were found for the transverse diameter. The striking character of these changes is well shown in Chart 4, for which the combined results of the 2 litter groups were used.

*Teeth.*—The upper and lower incisor teeth were erupted but they were smaller than those of normal new-born young. There was no consistent difference between the 2 sets with respect to the degree of eruption and no abnormalities of position were observed. The enamel frequently had a slightly bluish, semitranslucent appearance. The upper and lower molars were usually not erupted or only the point of an anterior tooth could be seen and one or two others felt through the gum.

*Tongue.*—In the majority of cases, the tongue was considerably larger and more fleshy than normal and its rounded tip generally protruded from the lips to a variable extent (Figs. 2, 4, and 16). In normal young, born dead or which have died shortly after birth, the tip of the tongue may frequently be seen between slightly parted lips but there is not often actual protrusion. In achondroplastic dwarfs with cleft palates, an unusual condition of the tongue was found. The actual size appeared to be normal or somewhat small and narrow because of the peculiar shape. The posterior portion was molded into a hump-back ridge which narrowed toward the dorsum into a flattened plateau; the base, in other words, was broader than the upper surface (Fig. 17). The anterior end was narrow and somewhat pointed rather than rounded and the extent of protrusion was usually not as marked as in the other cases (Figs. 3 and 5).

*Cleft Palate.*—A cleft palate was found in 56 of 224 achondroplastic animals, an incidence of 25.0 per cent; 4 animals were not examined for this condition.

The defect was equally divided between males and females. In the majority of cases, the cleft extended along the entire length of the roof of the mouth from the base of the upper incisors to the pharynx with the production of a long, uniform trough (Fig. 17). The width was variable, ranging from a very narrow slit to a cleft 2 to 3 or 4 mm. wide. In a few cases, the defect was less extensive, involving only the anterior portion of the hard palate. The base or floor of the trough was intact and covered with apparently normal mucous membrane.

*Ears.*—In many cases, the ears appeared to be large and distinctly fleshy. This condition was sometimes but not invariably associated with edema. For the most part, however, the ears were not remarkable and there was only one unusual feature, that of “folding” which was seen in a considerable number of animals. Its significance is uncertain.

In the great majority of normal new-born young, the ears are laid back smoothly and firmly with the outer surface in contact with the occiput and neck (Figs. 1, 4, 5, and 15) and only occasionally are folded ears seen. In this condition, one or both ears are turned forward, either in whole or in part. In the former case, the inner surface rests against the posterior portion of the cheek and the side of the head while in the latter case, the outer half or the tip is folded forward (Figs. 15 and 16).

*Body.*—The body of all achondroplastic dwarfs seemed very large in comparison with the extremities. Its length did not appear to be out of proportion to the size of the head but its width and depth were so pronounced as to increase the impression of marked disproportion (Figs. 1 to 4, 15, and 16).

The most conspicuous feature of the body was the extremely large, protuberant abdomen (Figs. 2 to 6, 15 to 17). It was especially prominent when the animal was placed on its side but it was almost as pronounced in the dorsal or ventral positions. The length and width of the ventral aspect and the depth of the cavity were greatly increased. There was only an occasional animal in which the size and prominence of the abdomen seemed less marked than was the rule.

In comparison with the abdomen, the thorax in its ventral aspect seemed somewhat small. It appeared to be shortened but increased in breadth (Figs. 2 to 6). Closer inspection together with palpation revealed a very shallow manubrial angle and a flaring or bulging costal margin which described a less angular course than in normal animals with respect to the spine as well as the sternum. The position of the lower ribs frequently added to the abnormal prominence of the abdomen (Figs. 15 and 16). The shape of the achondroplastic thorax might be described as a truncated pyramid in contrast with the oval shape of the normal animal.

*Spine.*—The dorsal aspect of the body displayed no unusual features with the exception of an increased width of the lower portion (Figs. 1 and 15) brought about by the condition of the abdomen and lower thorax just described.

The normal curvature of the spine was generally well preserved but in some cases, the back appeared flat (Fig. 5) while in a few others, there was a slight shallow concavity extending from the base of the skull to the pelvis (Fig. 4).

Measurements of the cervical, thoracic, and lumbar portions of the spine were made on x-ray photographs and the results were analyzed in the same manner as those of the extremities and skull. In the 2 litter groups under consideration, the mean decrease in length of these parts of the achondroplastic spine ranged from 18.3 to 29.1 per cent of the values for the normal sibs (Table II). But when the measurements were analyzed in relation to net body weight values, little difference was found between the achondroplastic dwarfs and their normal sibs with respect to the thoracic and lumbar portions (Table III and Chart 4). In the case of the cervical spine, however, the mean achondroplastic measurements exceeded that of the normal animals by 16.0 per cent, a result which may be inaccurate due to the difficulties of measuring this region.

*Tail.*—In all achondroplastic dwarfs, the tail was abnormal. It appeared to be considerably shortened while the base or root was comparatively broad. Very frequently they were described as fleshy, thickened, and spade-like (Fig. 3), and they contrasted sharply with the long, slender tails of normal new-born young (Figs. 1, 4, 5, 15, and 16). Reference to the x-ray photographs shows that there was extremely little, if any, ossification of the caudal vertebrae (Figs. 7, 11, and 19).

*Skin.*—A marked redundancy of the skin is one of the most striking features of achondroplasia in the rabbit. The contrast between this loose, redundant condition and the tight, smooth skin of normal new-born young, either living or dead, was very striking (Figs. 1, 4, 5, 15, and 16).

In practically all cases, conspicuous loose cutaneous folds or rolls were present in various areas. They were usually most extensive and pronounced in the cervical and shoulder girdle regions, the upper thorax and lower abdomen, the buttocks, and the proximal portions of the extremities (Figs. 2, 4, 15, and 16). The condition was frequently described as "elephant skin." The folds sometimes extended over the lower segments of both the front and hind legs (Figs. 5 and 17) and in extreme cases, the legs looked as if they were covered with oversized, wrinkled sleeves and trousers. In other areas, such as the lower thorax and dorsal regions, the skin was generally not redundant but relaxed and often finely wrinkled.

In many cases, the skin and subcutaneous tissues, particularly in the areas of redundancy, showed a pudgy, edematous thickening of variable degree. It was most conspicuous in the cervical and shoulder girdle areas and over the hind quarters. In marked contrast to the skin elsewhere, that of the abdominal wall was thin and delicate. It also might be flabby and flaccid (Fig. 16), although it frequently had a stretched, almost taut, appearance (Figs. 3, 6, and 17). Occasionally, it was slightly edematous but never as markedly so as in other areas.

The fur was often somewhat thin and short. There were no instances of nakedness but the condition appeared to be rather a subnormal development of all fur elements (Figs. 1, 4, 5, and 15). The whiskers, however, were well developed. There was also in a good many cases some deficiency of pigmentation, the dark or black areas of the skin having a dull, slightly grayish or

gun-metal cast. In connection with these findings, it will be remembered that while some of the animals were definitely premature, the majority were born at term.

*Muscles.*—With the conspicuous exception of the abdominal wall, the muscles generally appeared to be well developed. In some animals, the leg muscles, and particularly those of the hind extremities, seemed unusually prominent but this was not a constant finding. On the other hand, the abdominal muscles were, as a rule, much thinner than those of normal new-born young. In the cases in which postmortem autolysis was present, the abdominal muscles and skin were affected to a greater degree than is usually found in normal individuals.

A most striking feature was the failure of rigor mortis to develop. All dwarfs were soft, relaxed individuals and as far as could be determined, the entire musculature shared in this characteristic condition with the possible occasional exception of the facial muscles. It will be recalled that the great majority of dwarfs were found dead. It was not known, of course, whether they had ever shown rigor but in any event, their flabby, soft state contrasted sharply with the comparative firmness present in normal young found dead. Furthermore, the relaxation persisted under conditions of short or prolonged ice box storage or room temperature. The dwarfs which were found alive but which died within a few hours and others which were thought to have just died, were observed with particular attention for the development of rigor. In no instance was there any change approaching that which took place in normal young under similar circumstances.

*Sex.*—The disease is not sex-linked. Although female achondroplastics outnumber the males, the observed distribution is not significantly different from expected values as determined by the  $\chi^2$  test of homogeneity ( $N = 1$ ,  $P = 0.05+$ ). There is no unusual sex distribution in the non-achondroplastic young of this stock. Of 211 cases, 115 or 54.5 per cent, were females and 96, or 45.5 per cent, were males. The sex could not be determined in 5 partly destroyed animals and in 12 cases it was not recorded. The external genitalia of both sexes appeared normal.

#### RÉSUMÉ AND DISCUSSION

From the description of an hereditary abnormal form in the rabbit, it is evident that in many striking respects the condition closely resembles achondroplastic disease in the human, bovine, and canine species. The characteristic features of reduced size and disproportionately shortened extremities, the large squarish head, the flat or sloping chimpanzee-like face, the large protuberant abdomen, the redundant skin, together with the high incidence of still-births or non-viable young, are common in greater or less degree to the disease in the four species.

The condition in the rabbit is present at birth and is incompatible with



life. The great majority of cases are still-born or die very shortly after parturition. Of 228 cases, only 11 animals, or 4.8 per cent, were living when the litter was first examined a few hours after birth and of these, only 2 survived approximately 12 hours. In the living animals, respiration was rapid and shallow, body movements were sluggish, and there were but feeble attempts at nursing.

In all cases, the muscles generally were soft and flabby and lacking in tone. Two features in particular were especially noteworthy. Rigor mortis failed to develop and second, the muscles of the abdominal wall were extremely thin and relaxed.

The disease is hereditary. In anticipation of the results of genetic studies (13), it suffices to say here that the mode of inheritance is on the basis of a simple recessive unit factor. Achondroplastic animals are homozygous for the factor. No gross abnormalities or peculiarities in heterozygous animals of the stock which could be associated with the disease have been observed either at birth or in later life.

Achondroplastic rabbits are smaller than their normal sibs. On the basis of mean birth weight values, the size reduction was approximately one-third, 36.8 per cent, the value of their normal sibs, the mean weights being 33.7 and 53.3 gm. respectively (Table I). Furthermore, there was much less variation in the weights of achondroplastic young than was the case with their normal litter mates or other normal young of the same stock. The distribution curves of birth weights show that approximately three-fourths the achondroplastic animals, 72.0 per cent, fell in the 30 to 39 gm. class as compared with 11.3 per cent of the normal sibs, while the percentages of achondroplastic and normal sibs which exceeded 39 gm. in weight were 14.4 and 84.1 per cent respectively (Chart 1). These outspoken differences were again emphasized in the comparisons of body weights made in terms of the percentage of the weight of the heaviest sib of each litter (Charts 2 and 3).

Both the fore and hind extremities were markedly shortened. Measurements made on x-ray photographs of achondroplastic animals and their normal litter mates showed that the mean length of the humerus, radius, femur, and tibia ranged from 53.8 to 64.8 per cent of the respective normal values (Table II). In terms of net body weight and computing the differences for each individual litter, the mean percentage differences were 44.4, 43.3, and 43.8 per cent for the humerus, radius, and ulna respectively and 36.3 per cent for the tibia (Table III).

The spine showed less shortening than the extremities. The mean length of the cervical, thoracic, and lumbar portions ranged from 18.3 to 29.1 per cent of the corresponding values for the normal sibs (Table II). But, when these results were considered in terms of net body weight, there was little difference in the mean length values for the thoracic and lumbar portions of the achondroplastic animals and their normal litter mates; the mean length

for the cervical spine showed an increase of 16.0 per cent (Table III). The tail was short and fleshy and its base comparatively broad.

The head appeared to be comparatively large and the calvarium was prominent. The mean anteroposterior diameter, however, was found to be 19.4 and 19.8 per cent shorter than the mean value for the normal litter mates, while there was little difference in the transverse diameter (Table II). But, on the basis of net body weight, both diameters were increased over normal values, the mean figures being 43.8 per cent for the transverse and 15.1 per cent for the anteroposterior measurements respectively (Table III).

The curious appearance of the achondroplastic animal was enhanced by conspicuous folds of loose, redundant skin most numerous in the cervical and shoulder girdle regions and the hind quarters, and by a very large protuberant abdomen. The coat was usually thin and the teeth showed subnormal development. Folded or creased ears were more frequently present than in non-achondroplastic young. A cleft palate was found in 25.0 per cent of the cases. There were more female than male achondroplastic animals but the difference is not statistically significant. Finally, it should be noted that the great majority of litters were born at term and on the whole, the condition of the dwarfs did not indicate that death had taken place very long before littering. Judging from the condition of the lungs, many of the animals were born alive.

The classification of achondroplastic rabbits as dwarfs follows the nomenclature of the human disease. The term has also been applied to the condition in dogs and cattle.

According to Rosahn and Greene (14) the diagnosis of dwarfism in the rabbit is warranted when the birth weight of a rabbit is less than 50.1 per cent of its heaviest sib. Their material, which was derived from stocks of this colony, was particularly concerned with representatives of the hereditary Polish dwarf form. In this form, Greene (11) found that the weights of dwarfs average 35.4 per cent of the weight of the heaviest sib, the weights of the semi-dwarfs, 45.5 per cent, transmitters, 74.7 per cent, and normal members of these litters, 94.0 per cent. The smallest animals represent the homozygous lethal form and the transmitters, the heterozygous viable form. Semi-dwarf animals were thought to represent the chance occurrence of an hereditary size variation leading to a diminutive individual which had been rendered smaller by the action of the dwarf gene; such an hereditary size variation occasionally occurs in non-dwarf-transmitting Polish stock.

In the present material, 35.3 per cent of achondroplastic animals had birth weights which were less than 50.1 per cent of the weights of the heaviest sib as compared with 2.5 per cent of the normal litter mates, while 41.7 per cent had birth weights which fell in the 50.1 to 60.0 per cent classes as compared with 3.0 per cent of their normal sibs. Of the remaining animals, 9.6 per cent of the achondroplastic animals had weights which were 70.1 per cent or more of the weights of the heaviest sib, in contrast to 86.1 per cent of the normal litter mates. Thus, in a substantial number of cases, the birth weights conformed to Rosahn and Greene's classification of dwarfism or approached

it fairly closely. In this connection, however, it should be remembered that the present group contained several examples of hereditary Polish dwarf forms as a result of some early outcross matings with this stock (Figs. 15 and 16). In addition, there were a few examples of very small achondroplastic individuals (Fig. 5) whose birth weight relationships indicated a combination of the two conditions, that is, an achondroplastic modification of a Polish dwarf form.

Another normally proportioned small form originally derived from Belgian forebears was also occasionally represented in the stock through the father of the second achondroplastic litter. These animals were examples of a peculiar hereditary disease complex, one characteristic of which is size reduction (Fig. 5). They are usually born alive; the smaller forms survive but a few days while larger individuals may live for several weeks or for very much longer periods. The disease is further characterized by peculiarities in the quality and pigmentation of the skin and coat evident at birth or within the first days of life, by nutritional disturbances, and by premature senescence. None of the few cases in the present material had an achondroplastic appearance. A few examples of undersized runty types without other distinguishing features were also seen.

#### SUMMARY

An achondroplastic condition in the rabbit has been described. It is present at birth and is characterized by size reduction, by a disproportion of bodily parts, most marked in the extremities, and by an invariably lethal effect. The animals are still-born or die very shortly after birth.

In physical appearance and in the character of the skeletal changes as shown by x-ray photographs, achondroplasia in the rabbit has a remarkable resemblance to the disease in man and in cattle and dogs.

The condition which first occurred in offspring of pure bred Havana rabbits is inherited. In anticipation of the later discussion of this phase of the study (13), it can be stated that the mode of inheritance is on the basis of a simple recessive unit factor and that the appearance of non-achondroplastic transmitters (heterozygotes) is that of normal animals.

#### BIBLIOGRAPHY

1. Mörch, E. T., *J. Hered.*, 1940, **31**, 439.
2. Stephens, F. E., *J. Hered.*, 1943, **34**, 229.
3. Stockard, C. R., *The genetic and endocrine basis for differences in form and behavior*, Philadelphia, The Wistar Institute of Anatomy and Biology, 1941.
4. Crew, F. A. E., *Proc. Roy. Soc. London, Series B*, 1923, **95**, 228.
5. Mohr, O. L., and Wriedt, C., *Z. Tierzucht Zuchtungsbiol.*, 1925, **3**, 223.
6. Downs, W. G., *Anat. Rec.*, 1928, **37**, 365.
7. Carmichael, J., *Nature*, 1933, **131**, 878.

8. Punnett, R. C., *J. Genetics*, 1936, **32**, 65.
9. Brandt, G. W., *J. Hered.*, 1941, **32**, 183.
10. Gregory, P. W., Mead, S. W., and Regan, W. M., *J. Hered.*, 1943, **33**, 317.
11. Greene, H. S. N., *J. Exp. Med.*, 1940, **71**, 839.
12. Pearce, L., and Brown, W. H., *J. Exp. Med.*, 1945, **82**, 261.
13. Pearce, L., and Brown, W. H., *J. Exp. Med.*, 1945, **82**, 281.
14. Rosahn, P. D., and Greene, H. S. N., *Proc. Soc. Exp. Biol. and Med.*, 1935, **32**, 1580.

#### EXPLANATION OF PLATES

In all x-ray photographs of the entire animal the ventral surface of the body was in contact with the film, and in those of the skull the under surface of the chin was placed next the film.

All litters illustrated except that in Fig. 5 were born at term.

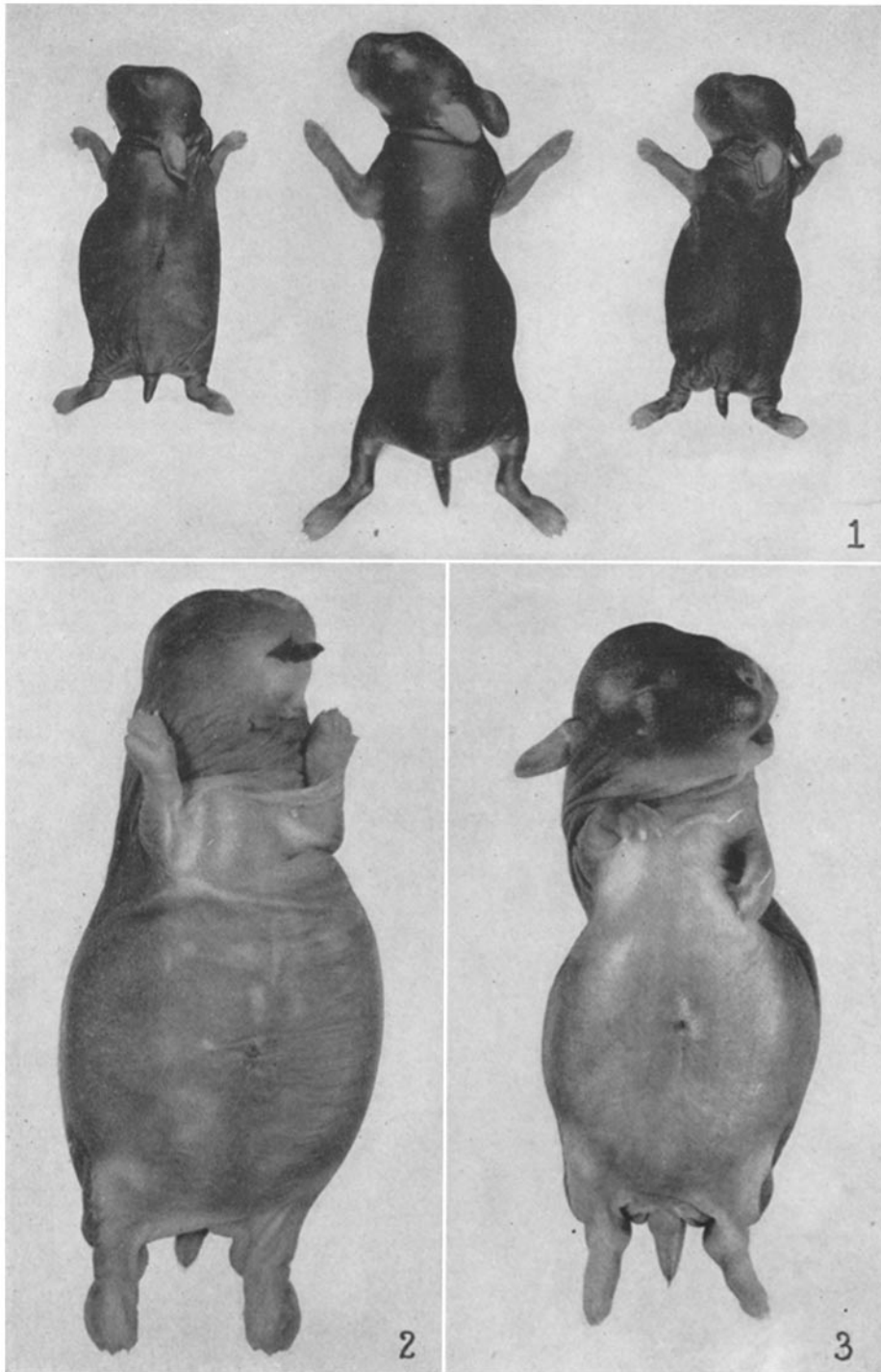
The photographs were made by Mr. J. A. Carlile.

#### PLATE 7

FIG. 1. Typical examples of achondroplasia. The litter contained 2 dead achondroplastic dwarfs and 3 living normal animals. Note the reduced size and the shortened extremities, the square broad head, and short spade-like tail of the dwarfs. The right hind foot of the dwarf on the right has only 1 well formed toe with nail; there are slight divisions of other toes but no nails. The left hind foot has nails but no decided toe divisions. The nasal depression is well marked in this animal but is comparatively slight in the dwarf on the left. The forelegs of the dwarfs were extended and the normal animal was anesthetized for the photograph.  $\times 0.48$ .

FIG. 2. Typical achondroplastic dwarf born dead; there were 5 normal living litter mates. Note the redundant skin with its prominent folds in the cervical, thoracic, and hind leg areas, the extremely large relaxed abdomen, the large protruding tongue, and the short fleshy tail. The divisions of the hind toes are indicated but are imperfectly formed and the nails are very small.  $\times 0.95$ .

FIG. 3. Achondroplastic dwarf born dead; there were 5 normal living litter mates. Note the marked cervical skin folds, prominent calvarium, shortened face with retracted nasal region, enlarged prominent abdomen, and shortened thorax. There was also a cleft palate.  $\times 1.0$ .



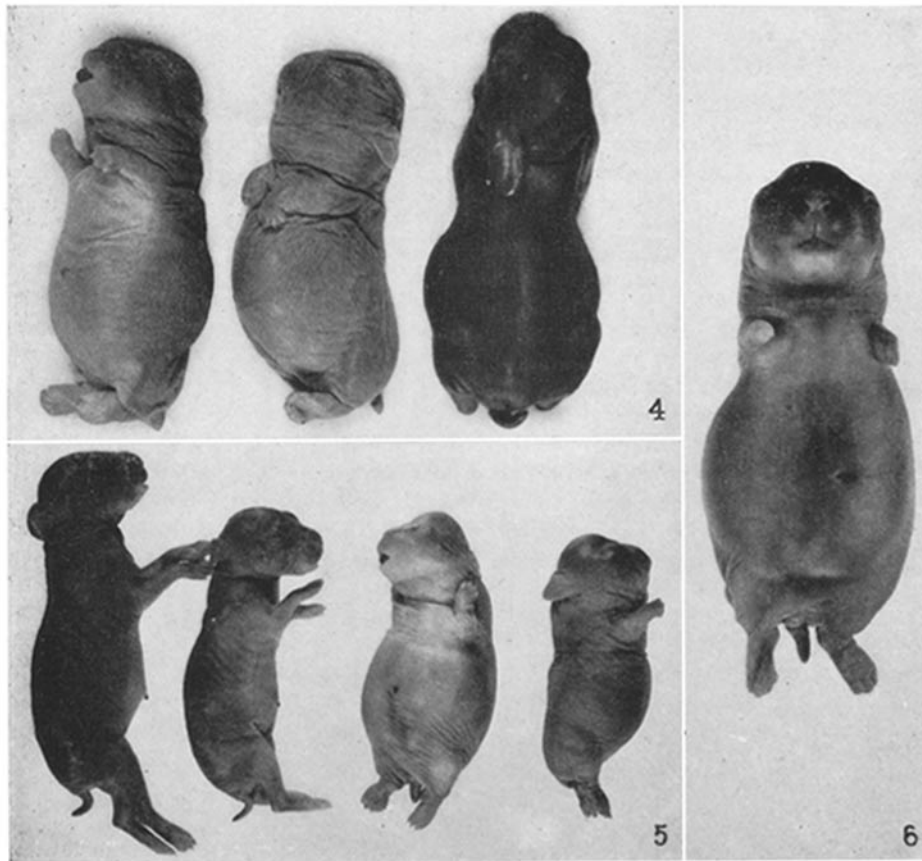
(Brown and Pearce: Hereditary achondroplasia in rabbit. I)

#### PLATE 8

FIG. 4. Two achondroplastic dwarfs born dead, with birth weights of 32 and 33 gm. respectively, and a normal living litter mate weighing 35 gm. The photograph was taken 2 days after the birth of the litter. The dwarfs show marked redundancy of the skin with prominent folds in the cervical, shoulder girdle, back, and upper leg regions. Both show deficient pigmentation and hair growth. The broad shape of the head and muzzle and large protuberant abdomen are especially marked in the second dwarf, which also shows some lordosis of the vertebral column.  $\times 0.58$ .

FIG. 5. Four animals of a litter of 9, 7 of which were living. This litter was born approximately 24 hours before term and all the animals were relatively small. The 2 animals on the left were anesthetized; the larger was normal. The second animal was a "downy-rusty-dwarf" or D. R. D. weighing 19 gm.; there were no achondroplastic stigmata. The 2 very small achondroplastic dwarfs on the right were born dead; they weighed 22 and 19 gm. respectively. Each had a cleft palate. A third as described in the text. The mother was the daughter of a pure bred Polish doe dwarf factor, the Polish, is represented in this litter who was a transmitter of the hereditary Polish dwarf factor. Compare with Figs. 15 and 16.  $\times 0.45$ .

FIG. 6. Achondroplastic dwarf born dead; there were 6 living normal young. The right front leg ends in a smooth rounded stump of the radius and ulna; there was no paw, toes, or nails. The left front foot has 1 toe, probably the outer, and 1 inner toe, probably the thumb; both toes were rudimentary. The hind feet were normal.  $\times 0.82$ .



(Brown and Pearce: Hereditary achondroplasia in rabbit. I)

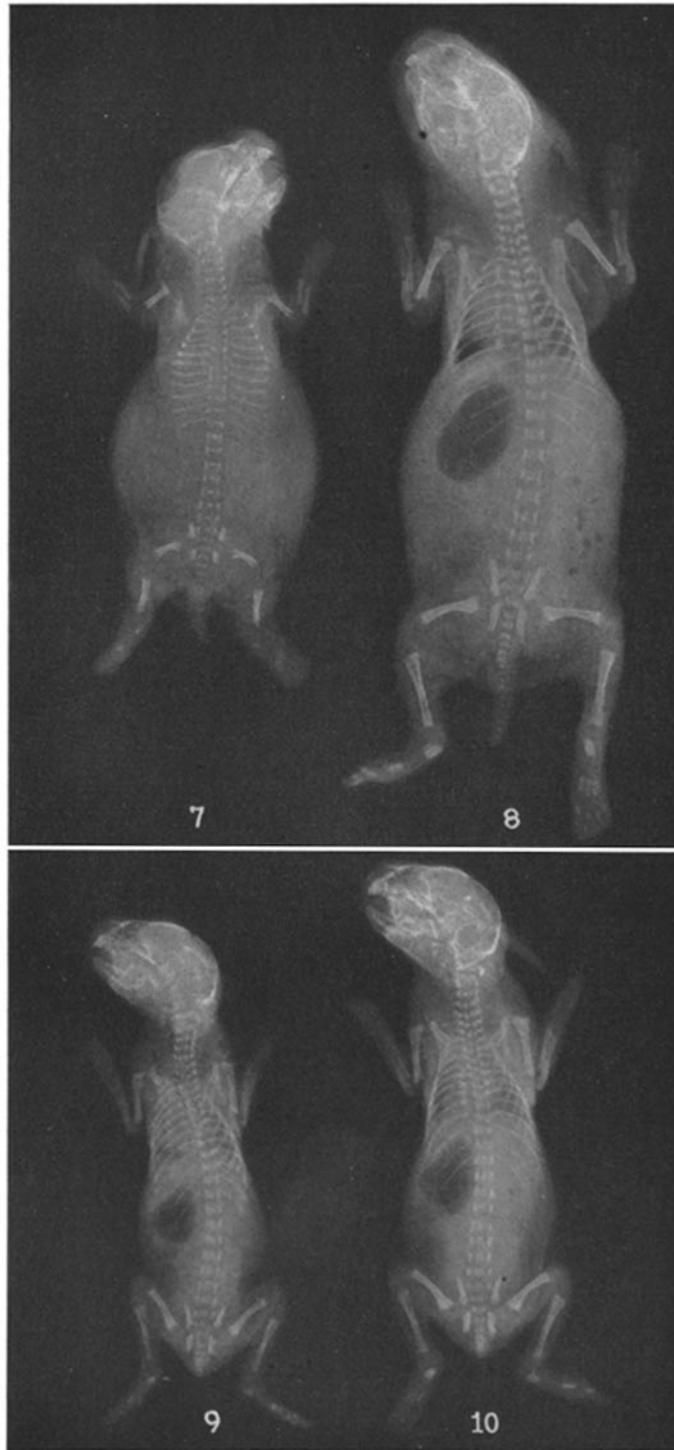
#### PLATE 9

Figs. 7 to 10. X-ray photographs of 4 animals in a litter of 7 young taken within a few hours of birth. There were 2 dead animals, an achondroplastic dwarf (Fig. 7) weighing 34 gm. and a normal animal (Fig. 8) weighing 58 gm. The lungs of both animals were inflated. Two living animals were anesthetized, a normal one (Fig. 10) weighing 35 gm. and a diminutive form of the "downy-rusty-dwarf" type (Fig. 9) weighing 25 gm.  $\times 0.79$ .

Note the characteristic skeletal abnormalities of the achondroplastic animal in Fig. 7. Bone dimensions should be particularly compared with those of the 2 non-achondroplastic litter mates of equal or smaller size shown in Figs. 9 and 10. All the long bones of the achondroplastic animal are markedly shortened and both portions of the pelvis are similarly reduced. There is a pronounced general deficiency of calcification, most marked in the bones of the fore and hind feet and the caudal vertebrae. The ends of the long bones are irregular, frayed, and tend to be cupped. The marrow cavities can scarcely be seen. The incisor teeth are subnormal. The squarish shape of the head, the transnasal depression, the extremely large abdomen, and the skin folds of the fore and hind quarters are also shown.

The non-achondroplastic animals (Figs. 8, 9, and 10) show nothing unusual. The bodily proportions of the diminutive D.R.D. sib are normal; there may be a slight ossification deficiency of the caudal vertebrae and the bones of the forepaws. In all 3 animals, the marrow cavities are well outlined. The oval, elongated shape of the skulls contrasts sharply with the squarish, blunt shape in the achondroplastic dwarf.





(Brown and Pearce: Hereditary achondroplasia in rabbit. I)

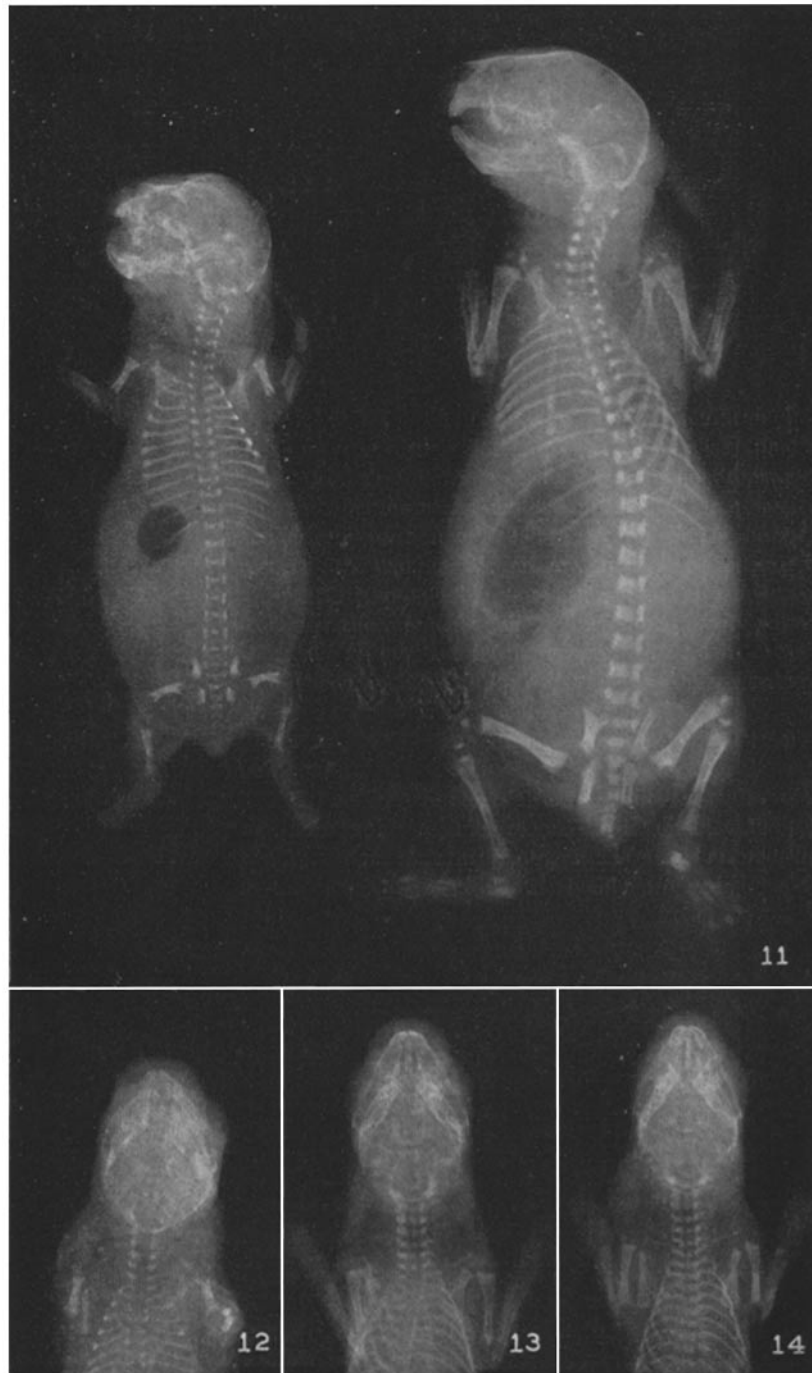PLATE 10

FIG. 11. X-ray photograph of 2 animals in a litter of 3 young taken approximately 24 hours after birth. Both animals were alive at 6 p.m. on the previous day but were found dead the following morning. The achondroplastic dwarf on the left weighed 30 gm. and the normal animal on the right, 67 gm. The degree of calcification in this achondroplastic animal is slightly greater than in the one pictured in Fig. 7. In other respects, the two photographs are practically identical.  $\times 1.0$ .

FIG. 12. X-ray photograph of the skull of an achondroplastic dwarf weighing 38 gm. Compare the rounded shape of the cranial cavity with its expanded transverse and shortened anteroposterior diameters with the long oval elliptical shape of the normal skull shown in Figs. 13 and 14. The less differentiated state of the elements of the skull base is also well shown.  $\times 1.0$ .

FIG. 13. X-ray photograph of the skull of a normal new-born rabbit weighing 32 gm.  $\times 1.0$ .

FIG. 14. X-ray photograph of the skull of a small or diminutive non-achondroplastic new-born rabbit weighing 24 gm. This animal was a litter mate of the one pictured in Fig. 12. Note that this photograph is entirely similar to that of Fig. 13 with respect to the shape of the skull, the bodily proportions, and the degree of calcification.  $\times 1.0$ .




(Brown and Pearce: Hereditary achondroplasia in rabbit. I)

PLATE 11

FIG. 15. Four of a litter of 5 young, containing 2 dead typical achondroplastic dwarfs weighing 32 and 37 gm. The two living normal animals on the right weighed 28 and 67 gm.; they were anesthetized with chloroform. There was also a dead normal animal of 48 gm. The concentration of Polish dwarf blood represented in this litter is expressed in the diminutive non-achondroplastic animal. Compare with Fig. 5.  $\times 0.4$ .

FIG. 16. Ventral view of the same animals pictured in Fig. 15. The right ear of the second achondroplastic dwarf has a folded tip. The fold was smoothed out to show its linear crease when the previous photograph was taken. Note the small pointed tip of the tongue of the first achondroplastic animal in which there was a large cleft palate.  $\times 0.4$ .

FIG. 17. Three typical achondroplastic dwarfs. In the one on the left, the roof of the mouth was intact while in both the others, there was a large cleft palate. The tongue of the first animal was large and flat with a rounded end. Those of the others showed a moulded dorsum or plateau formation and a pointed tip.  $\times 0.58$ .



(Brown and Pearce: Hereditary achondroplasia in rabbit. I)

PLATE 12

X-ray photographs of 3 of the new-born litter mates shown in Figs. 16 and 17 for comparison of the typical skeletal abnormalities of the achondroplastic animal with the normal skeletal outlines of a larger sib and of one of the same weight.

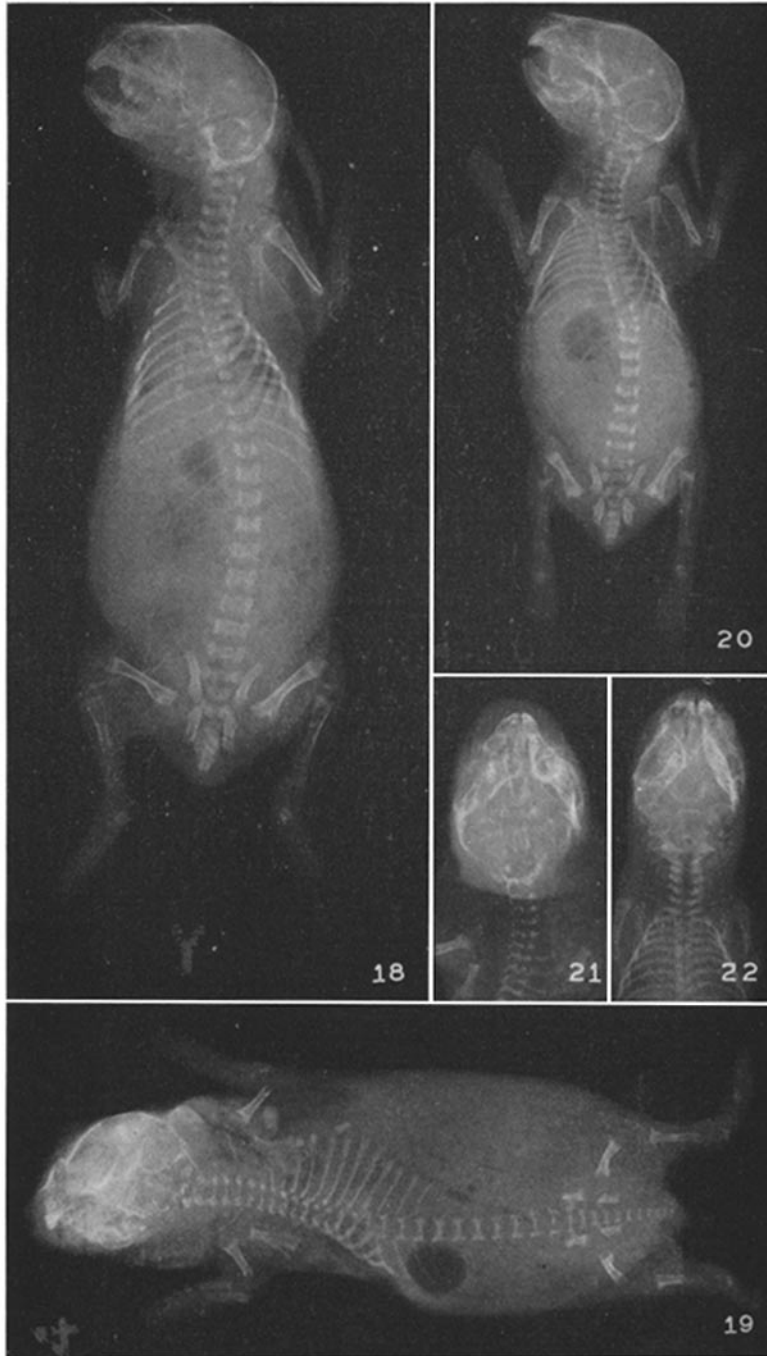
FIG. 18. Normal sib weighing 67 gm. Anesthetized. This is the right hand animal of Figs. 15 and 16.  $\times 1.0$ .

FIG. 19. Achondroplastic dwarf weighing 37 gm. Found dead. This is the second achondroplastic animal from the left in Figs. 15 and 16.  $\times 1.0$ .

FIG. 20. Diminutive normally proportioned sib weighing 28 gm. Anesthetized. This is the second animal from the right in Figs. 15 and 16.  $\times 1.0$ .

FIG. 21. Skull of the achondroplastic dwarf shown in Fig. 19. Note the characteristic rounded shape of the cranial cavity. Compare with Fig. 12.  $\times 1.0$ .

FIG. 22. Skull of the diminutive sib shown in Fig. 20. Note the normal oval elliptical shape as in Figs. 13 and 14.  $\times 1.0$ .



(Brown and Pearce: Hereditary achondroplasia in rabbit. I)