

HEREDITARY DISTAL FORELEG CURVATURE IN THE RABBIT

I. MANIFESTATIONS AND COURSE OF THE BOWING DEFORMITY: GENETIC STUDIES

By LOUISE PEARCE,* M.D.

(From *The Rockefeller Institute*)

PLATES 68 TO 72

(Received for publication, January 8, 1960)

Among the morbid conditions of the rabbit observed in a breeding colony maintained for the study of constitutional factors in health and disease (1), bone abnormalities of various types were observed and certain of them were found to have an hereditary basis. The manifestations of the conditions varied greatly. In achondroplasia (2) and osteopetrosis (3), for example, there were widespread bone involvement and an early fatal outcome whereas in oxycephaly (4) the comparatively minor skeletal changes were limited in distribution and general health was well maintained.

One of the less severe hereditary abnormalities described in this paper (5) comprised a "bowing" deformity of the lower or distal segment of the forelegs. The convexity of the curvature was directed inward toward the trunk, and the paws were held in a seal-like or "flipper" position pointing outwards away from the body. The condition was first observed in a family of pure bred Beveren rabbits and a little later in certain pure bred Belgian and French Silver stocks; several years afterwards it occurred in recently purchased Dutch stock. It was not observed in other families of these four breeds or in some fifteen other pure breeds, or in a very large number of hybrid and mongrel rabbits examined over a period of twenty years.

A brief description of the condition has previously been made (6).¹

DESCRIPTION OF FORELEG BOWING AND FLIPPER DEFORMITY

The appearance of the distal foreleg deformity in the rabbit will first be described. This is followed by a description of the development of the condition

* Dr. Pearce died, August 9, 1959.

¹ This preliminary note (6) referred to rachitic-like disorders observed in racial lines representing 6 breeds; the condition in 3 of these, the Beveren, the Belgian, and the French Silver, is the disorder described in the present paper. The note contains the statement that the deformity appears in the F₁ generation. The results of additional experiments, however, showed that this was not the case and also that the condition was not rickets.

beginning with the first clinical manifestation observed at 2 to 3 weeks of age and ending with the final stage of permanent bowing reached at 3 or 4 months of age. During this entire period an excellent state of health was maintained and body growth proceeded normally. No untoward features other than those of the lower foreleg were observed.

In its full expression the characteristic deformity comprised a lateral curvature of the ulna and radius, some flattening or compression of these bones, and generally an alteration in their relative positions. Because of the inwardly directed bowing, the paws pointed away from the midline and frequently also slanted anteriorly. The gait tended to be stumbling and awkward. In the great majority of cases both legs were affected and usually to an approximately equal degree. These several features are illustrated in the photographs reproduced in Figs. 1 to 7.

The adult rabbits whose photographs appear in Figs. 1 and 2 were aged 1 year 2 months, and 1 year respectively; the inward bowing of each was pronounced and of practically the same degree in both legs. There was also some anteroposterior twisting of the bones, together with flattening or "dishing" of the central portion, both of which features were more marked in the first (Fig. 1) than in the second rabbit (Fig. 2).

In rabbits which developed marked lateral bowing with pronounced flipper position of the paws, the contact area of the foreleg with the ground was not infrequently the carpal area or even the area over the distal ends of the radius and ulna. Such a radical shift from the normal postural relationship was brought about by a change to a higher level of the distal portion of the ulna and radius as compared with the flattened or lower level of their central portion of the bones. Actually this change in outline amounted to a second curvature and extreme cases are described as "corkscrew" legs.

An example of this very abnormal condition in a 4 months old rabbit is shown in the photograph reproduced in Fig 3. On the inner lateral and posterior surfaces of the forelegs can be seen oval whitish patches of thickened skin completely denuded of fur. These were the areas of contact of the forelegs with the ground; they were situated over the distal third or fourth of the radii which bore the forward weight of the body. An x-ray photograph of this rabbit taken at 4 years 10 months of age (Fig. 29) shows the abnormal curved and twisted outline of the foreleg bones, more marked in the case of the radius than the ulna, and the extremely distorted position of the paw.

There were some instances of obviously unequal degrees of lateral foreleg bowing, an example of which was a 3 months old rabbit whose photograph is depicted in Fig. 4.

In this instance the deformity was greater in the left than in the right foreleg. The considerable degree of flattening present in both legs was also more marked in the left leg and the flipper position of the left paw was more pronounced.

The deformity was well developed at an early age as can be seen in the photographs of 2 and 1 month old rabbits (Figs. 5 to 7).

The litter mate Beveren rabbits whose photograph appears in Fig. 5 were 66 days of age. The rabbit to the left had developed a well marked flipper deformity; the one on the right had none.

In the 56 days old rabbit pictured in Fig. 6 there was a considerable lateral bowing, somewhat more marked in the left leg. There was also moderate twisting or rotation of the right ulna and radius and a less pronounced rotation of the left leg bones.

The 1 month old rabbit whose photograph is reproduced in Fig. 7 was a typical example of the deformity at this early age. The legs showed approximately the same degree of bowing, although in the photograph the left leg appears to be somewhat more affected. Practically no rotation of the bones had taken place.

Before describing the characteristic manifestations of the development of the foreleg flipper deformity as they appeared from week to week, it is convenient at this point to refer briefly to the chief anatomical features of the distal foreleg bones of the normal rabbit.

In the adult rabbit (7) the shorter radius is anterodorsal to the longer ulna in its general position but crosses the ulna in such a way that its proximal extremity tends to be lateral while its distal extremity is medial. Both the proximal and distal extremities of the bones are immovably articulated with each other and their bodies or shafts are solidly united by the interosseous ligament. The radius and ulna are prevented from changing their positions with respect to each other. The radius is unable to rotate on an axis formed by the ulna as it does in man and the forefoot or paw is fixed in a position comparable to that of pronation in the human hand.

In the young adult rabbit 2 to 3 months of age, as well as in older animals, the free lateral surfaces of the bones are flat or very slightly curved and are practically parallel with each other. In the case of the radius, the central portion may be palpable as a slightly elevated or slightly curved area. The outer surface of the ulna may be felt as a very shallow depression; its barely perceptible curvature involves all or most of the shaft but is most apparent in the mid- and upper or proximal portions.

The distal extremity of the radius is largely formed by an epiphysis which is well marked even in older animals. It bears a grooved articular surface for articulation with the navicular and lunate bones of the carpus. The distal extremity of the ulna is formed by an epiphysis similar to but much longer than that of the radius. It is immovably articulated with the radius and its tip is formed by a blunt styloid process which is articulated with the triquetral bone of the carpus. After the growth period the epiphyses become firmly co-ossified with the body of the bone, although the lines of junction, or epiphyseal lines, are still visible even in old animals.

Development of the Foreleg Bowing Deformity

The course of development of the bowing condition from its earliest manifestation to the establishment of a permanent deformity will now be described. It is illustrated by a series of x-ray photographs of the distal foreleg segment of rabbits, taken at ages of from 13 days to 4 years 10 months; a similar series

of x-ray photographs of normal rabbits of comparable ages is also reproduced (Figs. 8 to 33).

The first indication of the bowing abnormality was an enlargement or thickening of the distal ulnar epiphysis at 2 to 3 weeks of age. Palpation of the external or free lateral surface of this area of the bone revealed a small rounded firm eminence which increased in size quite rapidly and within a week or two might be seen, as well as felt. The distal radial epiphysis showed only questionable enlargement. At about 3 weeks of age the forepaws began to assume a flipper position pointing outwards away from the longitudinal axis of the body.

A comparison of the x-ray photographs of the lower foreleg of affected and of normal rabbits at 2 weeks of age (Figs. 8 and 9) and at 3 weeks of age (Figs. 10 and 11) gives a good idea of the ulnar epiphyseal enlargement. The photographs show also the presence of definite irregularities of the epiphyseal cartilage margin, much more marked in the older rabbit (Fig. 10). The distal epiphysis of the radius of both flipper rabbits is possibly slightly expanded (Figs. 8 and 10).

At 3 to 4 weeks of age, inward bending of the distal half or third of the leg became palpable and increased rapidly both in degree and extent. The slender radius seemed to be more affected than the stockier ulna; that is, the degree of convexity of the inner surface of the radius seemed greater than the degree of concavity of the outer surface of the ulna. At about 6 weeks of age the bowing was usually visible and the flipper position of the paws was quite pronounced. The enlarged ulnar epiphysis continued to be very prominent.

These successive abnormal features are well shown in the x-ray photographs of rabbits aged 32 days (Fig. 12) and 43 days (Fig. 14); they contrast sharply with the normal developmental changes as shown in the x-ray photographs of the forelegs of normal rabbits, aged 32 and 39 days respectively (Figs. 13 and 15). By 6 weeks of age the abnormal features have become very conspicuous (Fig. 14). The degree of bowing of the distal half or two-thirds of the radius is pronounced; the bone appears to be curving around or over the markedly abnormal ulnar epiphysis. The carpus, metacarpus, and phalanges appear to be drawn or pushed to the side away from the normal midline position. The paw now points outward, not forward. The distal epiphysis of the ulna shows a greatly widened, deepened, and irregular expansion, but the degree of curvature of the bone is less pronounced than that of the radius. There is no more than a questionable expansion of the distal epiphysis of the radius.

By 2 to 3 months of age the bowing deformity and the flipper position of the paws were conspicuous. The extent of foreleg curvature now involved perhaps as much as the distal two-thirds of the radius and ulna. There was frequently a twisting of these bones as well, so that the medial surface of the radius overlapped the inner edge of the ulna to a variable extent and degree. In addition, there often occurred some flattening or depression of the lower portion of the shaft of the bones directed posteriorly, together with an anterior bulging or forward bending of the distal end itself. The term "dishing" will be used to describe such an abnormal surface. As the twisting and dishing of

the bones increased, the outwardly pointed paws thus acquired also an upward or anterior slant. The characteristic changes which took place during the 2nd and 3rd month of life are well illustrated in the 6 serial x-ray photographs of the left foreleg of the same rabbit taken at 41 to 77 days of age (Figs. 16 to 21). For comparison, x-ray photographs of the left forelegs of two normal rabbits, aged 51 and 78 days are shown (Figs. 22 and 23). Later x-ray photographs of the deformed rabbit taken at 111 and 153 days and at 10 months of age, are also reproduced (Figs. 24 to 26).

In the 6 x-ray photographs (Figs. 16 to 21) covering the 5 week period of from 6 to 11 weeks of age, the abnormal appearance of the greatly expanded and irregular distal epiphyseal cartilage of the ulna indicates a pronounced chondrodystrophic lesion. Cupping is a very prominent feature; it is less pronounced at 69 and 77 days of age (Figs. 20 and 21) than earlier. The degree of bowing attained by the radius is marked while that of the stockier ulna is moderate by comparison. Some twisting of the bones had occurred so that the distal third of the radius is seen to overlap the ulna in all 6 x-ray photographs. The direction in which the paw points is outward at an increasingly acute angle with the longitudinal body axis. There also appears to be some dislocation of the articulation of the styloid process of the ulna with the triquetral bone, well outlined in the x-ray taken at 54 days of age (Fig. 18). As the deformity increases the styloid process becomes directed more and more toward the midline, while the direction of the carpus is progressively outward away from the longitudinal axis. In the x-ray photographs taken at 69 and 77 days of age (Figs. 20 and 21) there is a considerable gap between the styloid process and the triquetral bone in the inner or medial portion of the joint while the actual articulation of the bones appears to be limited to the outer portion of the joint.

At about 3 months of age, the degree of bowing, twisting, and flattening of the foreleg bones had in the great majority of cases reached its peak and the final abnormal position of the paws had been attained. Only occasionally did the deformity continue to increase for a short time. The fully developed deformity was permanently maintained and no regression or improvement was observed. The character of the deformed bones in older cases is illustrated by x-ray photographs of the same rabbit just referred to taken at 111 days, 5½ months, and 10 months of age respectively (Figs. 24 to 26).

At 111 days of age (Fig. 24) it will be noted, as compared with the photograph taken at 77 days (Fig. 21), that there is no essential difference with respect to the marked curvature of both ulna and radius and their abnormal positional relationship, the extreme flipper position of the paw and the dislocated ulna-carpus articulation. A very considerable change, however, in the appearance of the distal ulnar epiphysis is evident, the x-ray at the older age (Fig. 24) clearly showing a pronounced regression of the earlier marked lesion (Fig. 21).

At 5½ months of age the appearance of the distal ulna epiphysis in an x-ray photograph (Fig. 25) is practically normal. The final photograph in the x-ray series of this rabbit taken at 10 months of age (Fig. 26) shows the typical permanent deformity of the curved and rotated radius and ulna, the dislocated ulna-carpus articulation, and the distinctive flipper position of the paw.

The characteristic features of the deformity in the adult flipper rabbit is

further illustrated by two x-ray photographs taken at 1 year, 2 months, and 4 years 10 months of age, respectively (Figs. 27 and 29).

In the x-ray photograph taken at 1 year 2 months of age (Fig. 27), the lateral bowing of the radius and ulna is well marked. There was some twisting or rotation of these bones, perhaps more of the right than of the left leg. The flipper position of the paws was not as pronounced as in the majority of cases and there was only a comparatively slight ulna-carpus dislocation.

The rabbit whose left foreleg is shown in the x-ray photograph of Fig. 29 was aged 4 years 10 months; a photograph of this animal at 4 months of age (Fig. 3) shows the thickened bare contact areas over the distal portion of both radii. Conspicuous in the x-ray photograph is the marked angular bowing of the radius and the very abnormal "hook" position of the paw. The ulna was bowed in a rather shallow curve with comparatively slight angulation. Both bones were flattened and twisted.

History of the Hereditary Foreleg Bowing Abnormality

Beveren Breed.—The first examples of the inward bowing deformity occurred in pure bred rabbits of the Beveren breed. The original Beveren stock of the colony comprised 1 male, No. 77-88, and 2 females, Nos. 77-89 and 77-90; none showed leg abnormalities. In a first generation litter, A102, the parents of which were 77-90 and 77-88, 4 of the 8 born survived; one female developed a moderate and another a slight foreleg deformity while a female and a male with normal legs were subsequently found to transmit the condition.

The second instance occurred in a backcross litter, BA2, the progeny of normal appearing parents; the mother was the female of the first litter and the sire was her father, 77-88. Nine of the 10 young survived and 4, a male and 3 females, developed foreleg bowing; a photograph of a deformed and a normal rabbit of this litter at 66 days of age is reproduced in Fig. 5.

In a third litter of 6 young, BA34, there were 3 survivors, 1 of which developed a moderate deformity. The deformed mother was a member of the second litter, BA2; the normal appearing father was a son of a female, 77-89, who was pregnant by an unidentified male when she was received in the colony.

The flipper Beveren stock was built up from the original three Beveren rabbits and individuals from the three litters just mentioned. It appeared highly probable from the early breeding results that the condition had an hereditary basis, but attempts to enlarge the stock adequately in order to study this and other questions were only slowly achieved. The Beveren stock was difficult to work with for several reasons.

In general, the Beveren female rabbits took poor care of their young, desertion and cannibalism being fairly common. There was also a rather high incidence of reproductive abnormalities such as fetal absorption, premature littering, prolonged pregnancy, poor milk supply, and sterility. In addition, accidental injuries to the young due to awkward movements of the deformed mother were encountered.

There were rather frequent instances in which some or all of a litter were non-viable at birth while others were weaklings which survived only a few days. Among nurslings and recently weaned young, the incidence of gastrointestinal disorders was variable but it was sufficiently frequent to be troublesome.

Two principle measures were employed to overcome these difficulties. First, a strict selection of both parents for breeding experiments was made on the basis of good health and

vigor and in the case of the female parent, of those whose previous litters, if any, had been well cared for and were generally robust and healthy.

Second, fostering all or a part of the litter was frequently employed, usually within a few days of birth and as a rule not more than 4 or 5 young were left with the mother. Later fostering up to 2 weeks or so of age was promptly attempted if the young were not thriving. Although many does refused to accept older and larger young, others received them without incident.

TABLE I
*Incidence and Grade of Foreleg Bowing in the Progeny of
Deformed Parents (Beveren Stocks)*

Litter groups arranged according to survival rates.

No. of litters	Total births	Deaths		Raised		Deformity			
		Early 1 to 6 days	Late 1 to 3 wks.	No.	Per cent	Marked		Moderate	
						No.	Per cent	No.	Per cent
Total 44	239	56*	13	170	71.1	158	92.9	12	7.1
Group A 28	155	17‡	6	132	85.2	123	93.2	9	6.8
Sub-groups A 13	73	—	—	73	100.0	66	90.4	7	9.6
7	40	6§	2	32	80.0	30	93.8	2	6.2
8	42	11	4	27	64.3	27	100.0	—	—
Group B 16	84	39¶	7**	38	45.2	35	92.1	3	7.9

Dead at birth or within a few hours:

*13 §6 ¶8
‡ 5 ||1 **1

The result of these procedures was rewarding and in time a suitable number of deformed rabbits were assembled for genetic studies. These are described in the following paper (5) but it can be stated here that the foreleg bowing abnormality was inherited on the basis of a single recessive unit factor. It was not sex-linked.

At the beginning of this study, gradations of the deformity varying from fair, to moderate, to marked degree were seen. Soon, however, the full expression of the character was apparently attained. This was the end result observed in 170 rabbits distributed in 44 litters, the offspring of 41 rabbits, 28 females and 13 males, all of which showed well marked foreleg bowing (Table I). The tabulated data have been arranged according to the survival rate of each litter.

Of the total 239 births, 69 non-survivors were distributed as follows: 13 young were non-viable at birth, 43 died within a day or so, and 13 within 1 to 3 weeks; 170 rabbits or 71.1 per cent were raised. Without exception all survivors developed a typical inward bowing of both forelegs, the condition being well marked in 158 or 92.9 per cent and moderate in 12 rabbits or 7.1 per cent respectively.

In 28 of the litters (Table I, group A) with survival rates of 64.3 to 100.0 per cent, there were 155 births; 132 rabbits or 85.2 per cent were raised. The deformity was marked in 123 or 93.2 per cent of the rabbits.

Group A was made up of 3 subgroups with different survival rates. In the first subgroup of 13 litters with 73 births, there were no deaths; in the second of 7 litters with 40 births, the survival rate was 80.0 per cent; and in the third subgroup of 8 litters with 42 births, the survival rate was 64.3 per cent. The incidence rates of marked deformity in these 3 subgroups were 90.4, 93.8, and 100.0 per cent respectively.

In group B, comprising the remaining 16 litters with 84 births, the comparatively low survival rates were distributed as follows: 2 litters, 33.3 per cent; 4 litters, 40.0 per cent; 9 litters, 50.0 per cent; and 1 litter, 59.1 per cent. There was a larger number of non-viable young and of weaklings than in the larger group A and in addition, satisfactory fostering conditions were not available. Of the 84 births, 38 individuals or 45.2 per cent were raised. A well marked deformity developed in 35 or 92.1 per cent of the rabbits.

The results of these breeding experiments showed that all surviving progeny of parents with well marked foreleg bowing developed a similar condition (Table I), and although there were considerable differences in the litter survival rates, varying from 45.2 to 100.0 per cent in the 4 litter groups, the incidence rates of well marked deformity were quite uniform, that is from 90.4 to 100.0 per cent. In the great majority of the 170 cases, both forelegs were bowed to approximately the same degree. There was no instance in which only one foreleg was affected.

Belgian and French Silver Breeds.—Soon after foreleg bowing was detected in the pure bred Beveren rabbits examples of a similar deformity were observed in certain of the pure bred Belgian and French Silver stocks of the colony. The condition in both these breeds closely resembled that in the Beveren stock with respect to the early age of its appearance, its progressive development during the first 2 to 3 months of life, and the character of the final and permanent deformity. There also appeared to be a familial distribution. The resemblance was further strengthened by the results of x-ray examinations and of gross and microscopic study of postmortem material. Finally, the identity of the abnormality in the three breeds was confirmed by the clean-cut results of appropriate breeding experiments.

Dutch Breed.—No other example of hereditary inward curvature of the forelegs occurred in any of the stocks of the colony including a large hybrid and mongrel population until several years after the original cases were noted when a fourth example was observed. At this time some pure bred Dutch rabbits unrelated to the Dutch stocks in the colony were purchased. As was the usual procedure with newly acquired stock, these rabbits were first interbred before

breeding with rabbits already in the colony and it was found that some individuals of the first generation progeny developed the typical foreleg and flipper deformity. It was not possible at the time to carry out complete test breeding experiments with this new stock but from the observations available there appeared to be no doubt that this fourth example of foreleg curvature was identical with that previously observed in certain pure bred Beveren, Belgian, and French Silver families.

Other Observations

Other observations on rabbits with the bowing deformity included blood chemistry determinations, hematologic examinations, and therapeutic tests. For the most part these studies were carried out on rabbits belonging to the Beveren stocks, and in the early days of the investigation. The great majority of the rabbits were 2 to 15 weeks of age. Normal unrelated rabbits of the same age served as controls.

Blood Chemistry.—The calcium, inorganic phosphorus, and alkaline phosphatase content of the blood of 42 deformed rabbits in 27 litters and 78 normal rabbits in 17 litters at 2 to 15 weeks of age were determined.² The distribution of examinations was as follows:—

Calcium:	181 tests on 42 deformed rabbits
	175 tests on 76 normal rabbits
Phosphorus:	183 tests on 42 deformed rabbits
	181 tests on 78 normal rabbits
Phosphatase:	183 tests on 41 deformed rabbits
	179 tests on 75 normal rabbits

The results are presented as smoothed mean values using weekly intervals.³ The value for calcium of the deformed rabbits decreased from an initial 13.5 mg. per 100 cc. at 2 weeks to 12.8 at 6 weeks of age; thereafter it gradually rose to 13.6 at 15 weeks of age. Slightly higher values, 13.6 to 14.0, were obtained for the normal rabbits except from the 4th to the 8th week when they were lower, 13.0 to 12.5.

The value for inorganic phosphorus for the deformed rabbits was 7.75 mg. per 100 cc. from 2 to 7 weeks of age with one exception, 7.6 at 6 weeks. From 7 to 15 weeks, the values steadily decreased to 6.2. For control rabbits the initial phosphorus values were smaller than those of the deformed animals except at 5 and 6 weeks when they were slightly higher. They ranged from 7.2 at 2 weeks, to 7.9 at 5 weeks, and 5.2 at 15 weeks respectively.

These results are embodied in the Ca × P product curves shown in Chart 1. Both curves describe a generally declining outline, the curve for the deformed rabbits being at a some-

² Serum calcium was determined by the Clark-Collip modification of the Kramer-Tisdall method (11). Serum inorganic phosphorus and the phosphatase activity of the serum were determined by Bodansky's methods (12).

³ The curves obtained by plotting the actual results were smoothed by the formula $\frac{a+2b+c}{4}$, the initial value of each curve being smoothed by the formula $\frac{2b+c}{3}$ and the final value by the formula $\frac{a+2b}{3}$.

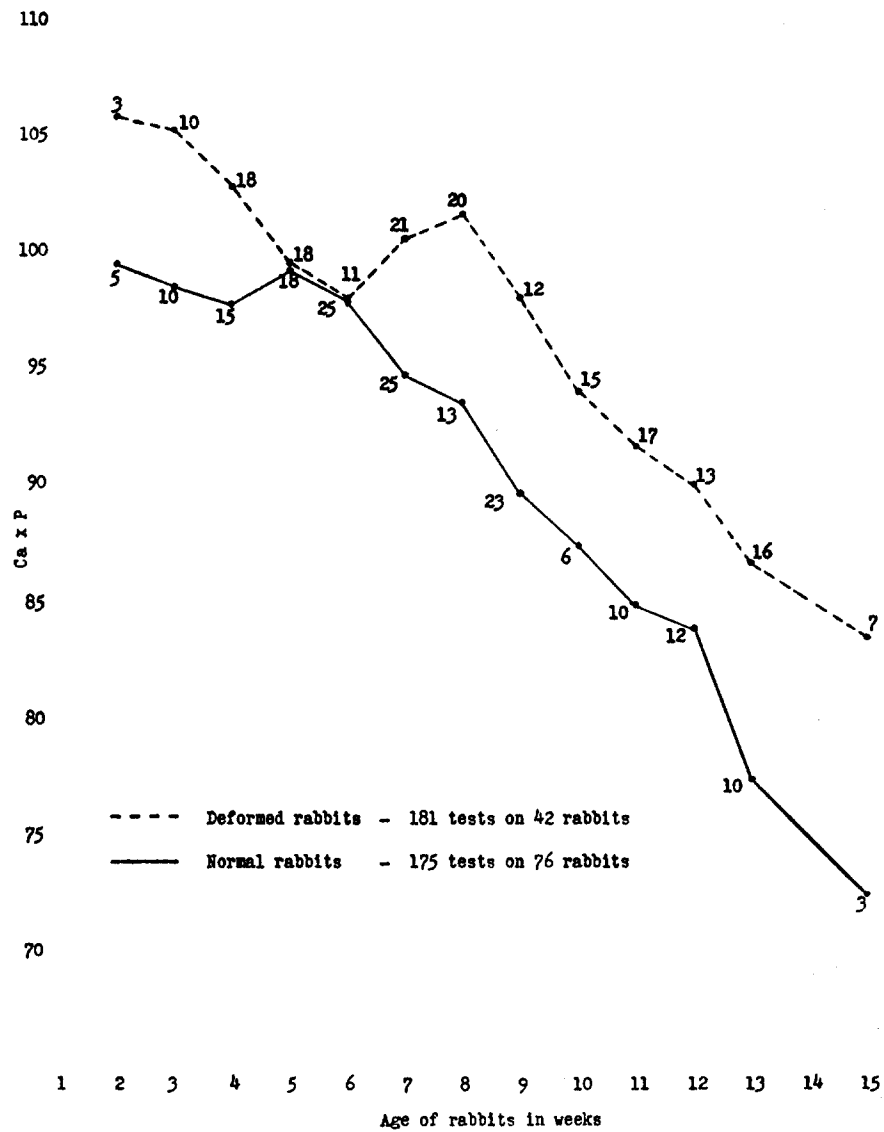


CHART 1. Blood calcium \times inorganic phosphorus product of deformed and normal rabbits expressed in smoothed weekly mean values. Numbers refer to the number of tests made in each week.

what higher level than that for the controls. The initial 2 week mean value for the deformed rabbits is 107 as compared with 99 for the controls while the final values at 15 weeks are 83 and 72 respectively. The difference in the weekly mean product values of the deformed and normal groups is approximately the same, that is, 5 to 10 except at the 5th and 6th weeks when almost identical values obtain.

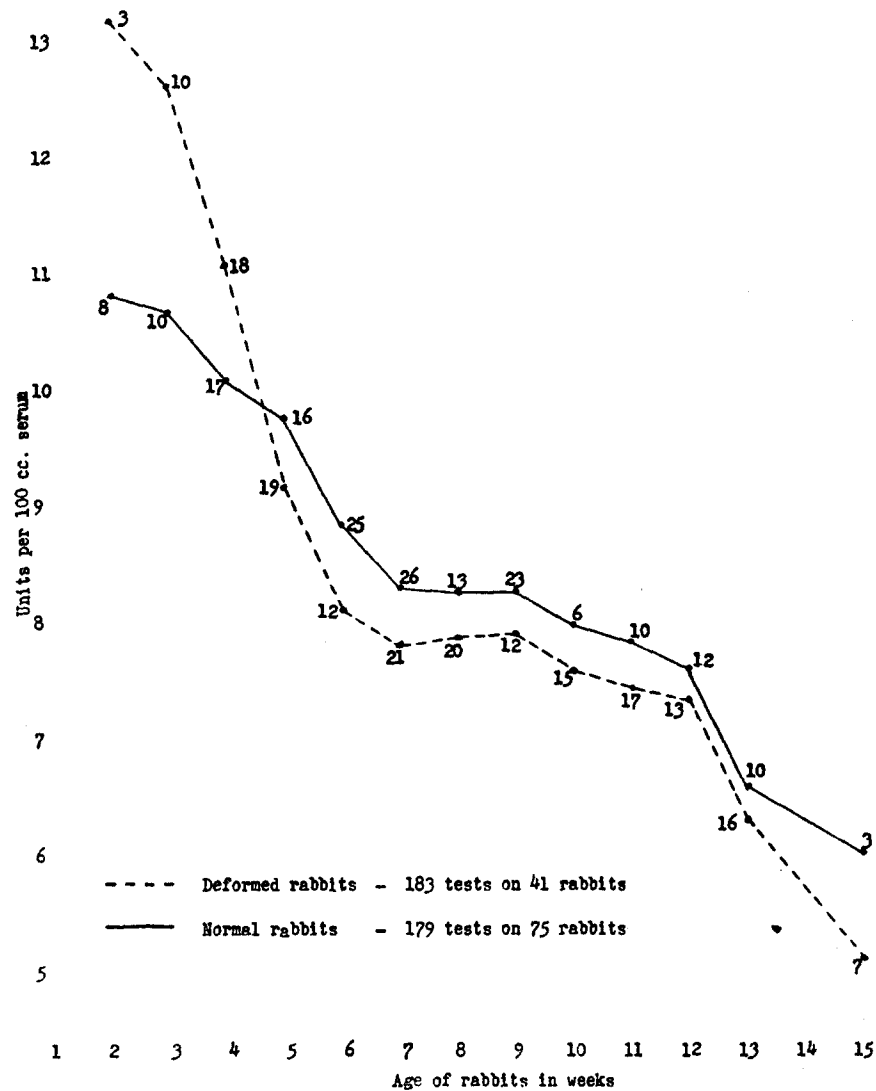


CHART 2. Alkaline phosphatase content of the blood of deformed and normal rabbits expressed in smoothed weekly mean values. Numbers refer to the number of tests made in each week.

The mean weekly alkaline phosphatase values are represented by the smoothed curves shown in Chart 2. Both curves describe an uninterrupted descending course from the highest values at 2 weeks to the lowest values at 15 weeks of age: deformed rabbits 13.2 to 5.1 units per 100 cc.; normal rabbits 10.9 to 6.0. The impressive features of the results are the considerably higher phosphatase values for the young deformed rabbits as compared with those for the normal rabbits and second, the very precipitous and extensive drop in the first 7

weeks of the values for the deformed animals; that is, from 13.2 to 7.8. The curve crosses that for the normal rabbits in the 4th week and thereafter continues at slightly lower levels for the remainder of the observation period.

Hematologic examinations, including differential white blood cell counts, were carried out on a considerable number of deformed rabbits at various ages from 1 and 2 weeks to 4 months of age. The results were entirely negative.

Therapeutic Experiments.—At the beginning of this work, the possibility that the condition might be a peculiar form of rickets was considered, chiefly on the ground of the appearance of the ulna lesion in x-ray photographs and postmortem material. There were obvious objections to the idea, such as the limitation of primary lesion involvement to a single focus. However at this stage of the study it seemed desirable to carry out certain exploratory therapeutic experiments. The results of all of them were negative.

The administration of viosterol or haliver oil, beginning on the day of birth and continuing through the nursing period of approximately 2 months, was without effect either on the time of initiation of the ulna lesion or its course or on the development and character of the foreleg bowing. Similar treatment of the mother begun at the time of mating, that is, 1 month before littering and continued through pregnancy and the nursing period, with or without treatment of the young, was likewise without effect. There was also no response to repeated exposure of the nurslings to direct sunlight. Finally, fostering with an unrelated doe had no effect on the development of the ulna lesion and bowing deformity.

Sporadic Cases of Non-Hereditary Foreleg Bowing

Occasional instances of distal foreleg bowing in which an hereditary basis could not be demonstrated were observed every now and then in pure bred and mongrel stocks. They occurred in a haphazard fashion with no familial pattern of distribution. The bowing was usually directed inward as in the hereditary deformity of the Beveren, Belgian, French Silver, and Dutch stocks described in the present report, but examples of outward bowing were also seen. Examples of the sporadic condition are illustrated by the x-ray photographs of 2 rabbits aged 32 and 66 days of age reproduced in Figs. 30 and 31. An example of outward foreleg bowing in an adult rabbit aged 2 years, 8 months, is shown in the photographs reproduced in Figs. 32 and 33.

The development of these occasional cases of bowed forelegs was generally associated with malnutrition in the first few weeks of life during the early period of bone growth. Usually the rabbits were thin and did not thrive, gastrointestinal disturbances were noted, and body growth was retarded, and it seemed clear that metabolic disturbances were definitely implicated. Only exceptionally could the animal be raised to adult age.

Although the infrequent and spotty distribution of these cases made it appear unlikely that inheritance played any part in the development of the condition, the possibility was investigated by means of appropriate breeding tests. Whenever possible the parents were again bred and in addition interbreeding of near relatives was carried out. The deformed rabbits which survived to adult age were bred to near relatives and, in addition, to deformed individuals of the flipper Beveren stock. The results of all these test experiments were consistently negative.

GENETIC STUDIES

The rabbits with which the genetic studies were made comprised the following 4 groups:

I. 19 deformed animals of the Beveren stock, 5 males and 14 females.

II. 52 F_1 hybrid rabbits, the offspring of 10 deformed Beveren rabbits and 19 normal rabbits of 4 unrelated pure breeds. The deformed Beveren parents numbered 5 males and 5 females; the 19 normal parents comprised 1 male and 2 females of Dutch stock, 3 males and 3 females of Havana stock, 2 chinchilla females, and 4 males and 4 females of the English breed. The 52 F_1 hybrid Beveren progeny was distributed as follows:

Dutch-Beveren	3 males	8 females
Havana-Beveren	4 "	13 "
Chinchilla-Beveren	1 "	6 "
English-Beveren	3 "	14 "
	<u>11 males</u>	<u>41 females</u>

III. The F_2 progeny of $F_1 \times F_1$ hybrid parents, comprising 598 animals contained in 90 litters (Table II).

IV. The backcross progeny of F_1 hybrid \times deformed Beveren stock, comprising 284 animals contained in 45 litters (Table III). Deformed Beveren parents were the mothers of 16 and the fathers of 29 litters, respectively.

The period of observation of F_2 and backcross offspring was at least 8 weeks, during which examinations were carried out two or three times a week. An extensive x-ray study of affected and normal forelegs included serial photographs taken at frequent intervals. In addition, x-ray photographs of the skeleton of normal F_2 litter mates as well as of F_1 and of various other undeformed rabbits, were made. At the conclusion of the experiments the deformity was graded as well marked, moderate, or fair while the general character or type of bone was described as slender or stocky, light or heavy.

The pathologic observations comprised postmortem examination of deformed rabbits of various ages and the microscopic study of the affected bones and others as also of representative organs and tissues. The rabbits were killed by an injection of air into a marginal ear

TABLE II

Incidence of the Foreleg Bowing Deformity in F_2 Test Breeding Experiments

The composition of the subgroups designated by capital letters is explained in the text.

Group	No. of litters	Total births	Deaths		Total raised		Deformity			
			Early	Late	No.	Per cent	Negative		Positive	
							No.	Per cent	No.	Per cent
Total	90	598	107	36	455	76.1	342	75.2	113	24.8
A	76	495	49	25	421	85.1	313	74.9	108	25.5
B	55	371	16	12	343	92.5	266	77.5	77	22.5
C	34	207	—	—	207	100.0	163	78.7	44	21.3
D	74	484	94	26	364	75.2	265	72.8	99	27.2
E	47	301	14	10	277	92.1	210	75.8	67	24.2
F	29	160	—	—	160	100.0	123	76.9	37	23.1

vein. Histologic preparations were fixed as routine in Petrunkevitch's cupric-phenol solution and Susa fixative and stained with hematoxylin and eosin, Heidenhain's azocarmine-aniline blue stain, or von Kóssa's silver nitrate stain.

TABLE III
Incidence of the Foreleg Bowing Deformity in Backcross Progeny

Parents	No. of litters	Total births	Rabbits raised		Deformity	
			No.	Per cent	No.	Per cent
33 F ₁ hybrid Beverens × 18 Beveren stock	45	284	226	79.6	111	49.1
26 F ₁ hybrid Beveren females × 4 Beveren stock males	29	196	146	74.5	74	50.7
14 Beveren stock females × 7 F ₁ hybrid Beveren males	16	88	80	90.9	37	46.3

Results of Test Breeding Experiments

The F₁ hybrid crosses of deformed Beveren stock will first be referred to and then the results of the F₂ and the backcross test breeding experiments will be described.

F₁ Beveren Hybrid Crosses.—A total of 52 F₁ hybrid Beveren rabbits, comprising 11 males and 41 females, were observed. The forelegs of each rabbit were normal in appearance, and x-ray examination disclosed nothing unusual.

The Beveren stock rabbits used for F₁ hybrid matings were characterized by a well marked bowing deformity of the forelegs. In none of the families of the 19 representatives of the Dutch, Havana, chinchilla, or English pure breeds employed for hybridization had an inherited leg deformity developed during an observation period of several years, or subsequently, that is to say after the termination of these investigations. It should be noted in this connection that certain groups of these families were extensively inbred. The radius and ulna in the great majority of these rabbits were perfectly straight; in some individuals the outline of the bones was slightly or just palpably curved. There was no flattening or twisting of the bones. A survey of other pure breeds and of numerous hybrid and mongrel rabbits in the colony revealed only scattered instances of a similar slightly curved outline of the lower foreleg bones.

In the comparatively heavy-boned Havana breed, this slight curvature occurred somewhat more frequently than in other stocks, and although it was more prominent in some individuals than in others, it was never greater than gentle or slight to fair. Continued inbreeding resulted neither in an increased incidence nor an accentuation of the slight curvature.

In none of the 52 F₁ hybrid rabbits did foreleg bowing develop. The lower foreleg bones of 40 animals were perfectly straight while in 12 rabbits, or 23.1 per cent, they were very slightly curved. The distribution of these 12 rabbits with respect to the breed used for hybridization was as follows: in 2 of the 11 Dutch, in 8 of the 17 Havanas, in 1 of the 7 chinchillas, and in 1 of the 17 English. In 5 of the 17 Havana-Beveren rabbits, the curvature was more prominent than in the other 12 and perhaps was slightly greater than that observed in some of the pure bred Havana stock, but in no case could it be compared with the Beveren bowing. This finding which occurred in the early Havana-Beveren crosses suggested the

possibility of some type of hereditary leg abnormality carried in the Havana stock. However no clear evidence to support this idea was forthcoming from the results of repetitions of these matings or of other crosses of these two breeds.

F₂ Breeding Tests.—The F₂ progeny of F₁ × F₁ hybrid Beveren rabbits comprised 598 births contained in 90 litters (Table II). Among this offspring there were 143 deaths; 107 young or 17.9 per cent were non-viable at birth or died within a few days while 36 or 6.0 per cent died in from 2 to 5 weeks of age. A net total of 455 F₂ rabbits or 76.1 per cent of the total births were observed for at least 8 weeks. Of these 455 rabbits, 113 developed well marked inward bowing of both lower foreleg segments, together with a typical flipper position of the forepaws, an incidence rate of 24.8 per cent. No deformity developed in 342 or 75.2 per cent of the rabbits.

An analysis of these results from the standpoint of survival rates of individual litters will now be made:

There were 76 of the 90 litters in which 85.1 per cent of the young lived at least 8 weeks (Table II, group A). Of the 495 births, 421 rabbits were raised and 108 of them, or 25.5 per cent, developed the bowing deformity.

There were 55 litters with the high survival rate of 92.5 per cent (Table II, group B). Of 371 births, 343 rabbits were observed for 2 months or longer. Foreleg bowing developed in 77 rabbits, an incidence rate of 22.5 per cent.

All the young of 34 litters were raised (Table II, group C). Of this group of 207 rabbits, 44 developed a typical foreleg deformity, an incidence rate of 21.3 per cent.

The results of the F₂ test breeding experiments have also been considered in another way, that is, with the omission of 16 litters for the reason that one or both parents of these were not represented by other F₂ progeny: 14 litters were the only progeny of their respective mothers, 1 litter was the only offspring of the male parent, and 1 litter was the only progeny of both parents. In the remaining 74 litters (Table II, group D), there were 484 births of which 364 animals or 75.2 per cent survived. The foreleg deformity developed in 99 rabbits, an incidence of 27.2 per cent.

The 55 litters with the high survival rate of 92.5 per cent (Table II, group B) included 8 of the 16 litters just mentioned. With their exclusion, analysis of the results (Table II, group E) showed that in 47 litters containing 301 births, 277 or 92.1 per cent of the young were raised. Of this number, 67 rabbits developed foreleg bowing, an incidence rate of 24.2 per cent.

Of the 34 litters in which all animals survived (Table II, group C) one or both parents of 5 litters were not otherwise represented by F₂ progeny. With the omission of these 5 litters (Table I, group F), analysis of the results on 29 litters comprising 160 births showed that 37 or 23.1 per cent of the rabbits developed the foreleg deformity.

In these F₂ test breeding experiments comprising a total of 455 rabbits, the incidence rate of the foreleg bowing deformity was 24.8 per cent. Incidence rates of from 21.3 to 27.2 per cent were found for several components or subgroups of the total number so classified on the basis of various survival rates and also on the frequency of representation of the F₁ parents.

Backcross Breeding Tests.—These experiments were carried out with 33 F₁ hybrid Beveren rabbits with normal legs and 18 Beveren stock rabbits with deformed forelegs (Table III). Of the F₁ hybrid parents there were 26 females and 7 males and of the Beveren stock group there were 14 females and 4 males. The backcross progeny comprised 45 litters; of the 284 births 226 rabbits or 79.6 per cent were raised. A well marked deformity developed in 111 rabbits, an incidence rate of 49.1 per cent.

In 29 of the backcross litters the normal appearing F₁ hybrid Beveren parent was the mother (Table III). For these matings 26 F₁ females and 4 males of the Beveren stock were used. The births numbered 196 of which 146 rabbits or 74.5 per cent were raised. A typical deformity developed in 74 rabbits, an incidence rate of 50.7 per cent.

In 16 of the backcross litters, the sire was an F₁ hybrid Beveren and the mother a Beveren stock rabbit, the actual numbers used being 7 F₁ males and 14 stock females (Table III). There were 88 births, of which 80 rabbits or 90.9 per cent were raised; 37 rabbits or 46.3 per cent, developed the foreleg bowing deformity.

TABLE IV
Incidence of Foreleg Bowing Deformity in Backcross Progeny Arranged in 4 Groups According to the Non-Beveren Breed of the F₁ Hybrid Parent

Distribution of non-Beveren breeds used in the hybridization of F ₁ Beveren crosses	No. of backcross litters	Total births	Rabbits raised		Deformity	
			No.	Per cent	No.	Per cent
2 English males × Beveren females	4	21	19	90.5	8	42.1
14 English females × Beveren males	16	108	71	65.8	37	52.1
	20	129	90	69.8	45	50.0
4 Havana males × Beveren females	9	46	42	91.3	21	50.0
13 Havana females × Beveren males	3	17	17	100.0	8	47.0
	12	63	59	93.7	29	49.2
1 Dutch male × Beveren females	3	21	19	90.5	8	42.1
4 Dutch females × Beveren males	5	41	32	78.1	15	46.9
	8	62	51	82.3	23	45.1
1 Chinchilla female	5	30	26	86.7	14	53.9
1 Dut. BA male × BA stock females	3	21	19	90.5	8	42.1
2 Eng. BA males × BA stock females	4	21	19	90.5	8	42.1
4 Hav. BA males × BA stock females	9	46	42	91.3	21	50.0
4 Dut. BA females × BA stock males	5	41	32	78.1	15	46.9
5 Chin. BA females × BA stock males	5	30	26	86.7	14	53.9
14 Eng. BA females × BA stock males	16	108	71	65.8	37	52.1
13 Hav. BA females × BA stock males	3	17	17	100.0	8	47.0

BA, Beveren; Dut., Dutch; Hav., Havana; Chin., chinchilla; Eng., English.

The results of the backcross breeding tests have also been analyzed on the basis of the 4 breeds used for the hybridization of the F₁ parents and in each of the 4 groups, a further comparison from the standpoint of the sex of the F₁ parent has been made (Table IV).

The 4 non-Beveren pure breeds represented in the parentage of 37 F₁ rabbits had the following distribution for 32 females: 14 English, 1 chinchilla, 4 Dutch, and 13 Havana breed respectively. For 7 F₁ males: 4 Havana, 2 English, and 1 Dutch breed respectively. The total

number of 16 English crosses was much larger than the 7 Havana, the 5 Dutch, and the 5 chinchilla crosses, and although there are considerable variations in size of the various groups to be compared, still the results on the whole are fairly uniform.

The largest number of litters and progeny were those in which the F_1 parent was an English-Beveren cross (Table IV). In 20 litters there were 129 births of which 90 rabbits or 69.8 per cent were raised. Of this number, 45 rabbits or 50.0 per cent developed the bowing deformity of the lower forelegs.

In the group with an Havana-Beveren F_1 parent there were 12 litters with 63 births; 59 rabbits or 93.7 per cent were raised. Foreleg bowing developed in 29 rabbits, an incidence rate of 49.2 per cent.

In the group with a Dutch-Beveren F_1 parent, there were 8 litters containing 62 births, of which 51 rabbits or 82.3 per cent were raised. A foreleg deformity developed in 23 rabbits, an incidence rate of 45.1 per cent.

In the smallest group the chinchilla-Beveren F_1 parentage was represented by only 1 female. Her progeny comprised 5 litters with 30 births of which 26 rabbits or 86.7 per cent were raised. Foreleg bowing developed in 14 rabbits, an incidence rate of 53.9 per cent.

In the English-Beveren groups, the incidence rates for the offspring of an F_1 hybrid sire and mother were 42.1 and 52.1 per cent, respectively. For the Havana-Beveren progeny, the values were 50.0 and 47.0 per cent, and for the Dutch-Beveren progeny, 42.1 and 46.9 per cent, respectively. The progeny of the female chinchilla-Beveren F_1 cross had the highest incidence rate, 53.9 per cent.

A further comparison of the incidence rates of the deformity shows a somewhat greater variation in the progeny of the 3 male than of the 3 female F_1 parent groups, the respective values being 42.1, 50.0, and 42.1 per cent as compared with 52.1, 47.0, and 46.9 per cent, respectively (Table IV). Of the progeny of 7 F_1 hybrid sires, 80 rabbits were raised, and in 37 of them foreleg bowing developed, an incidence of 46.3 per cent. The raised progeny of 21 F_1 hybrid mothers numbered 120 rabbits and in 60 or 50.0 per cent, foreleg bowing developed. With the inclusion of the results for the progeny of the F_1 chinchilla female, the incidence rate is practically the same; that is, 50.7 per cent.

In summary, the results of these several test breeding experiments showed first, that the F_1 progeny of deformed Beveren rabbits and normal rabbits of other pure breeds did not develop the deformity. Second, certain of the F_2 progeny of $F_1 \times F_1$ hybrid Beveren parents developed typical foreleg bowing, the incidence rate being 24.8 per cent (Table II). Third, in the backcross offspring of F_1 hybrid Beveren \times deformed Beveren rabbits, the incidence rate of the deformity was 49.1 per cent (Table III).

DISCUSSION

The hereditary skeletal abnormality of the rabbit here described comprised a well defined bowing deformity of the ulna and radius, the convexity of the curvature being directed inward toward the midline and with the paws held in a flipper position pointing outward. The first manifestation was an enlargement of the distal epiphysis of the ulna palpable at about 2 weeks of age; bowing of both ulna and radius soon developed and increased rapidly and by 6 weeks of age the deformity was well marked. Both lower forelegs were similarly

affected and to approximately the same degree. No other skeletal areas were involved. There was also no dwarfism.

As revealed by x-ray photographs and also postmortem material to be described (5), the distal epiphysis of the ulna showed marked expansion and great irregularity of the epiphyseal cartilage and usually pronounced cupping. The only change in the epiphyseal cartilage of the radius seen in x-ray photographs was a possible minor, or very slight, widening. However, bowing of the slender radius took place at practically the same time as that of the heavier ulna because of the firm immovable articulation provided by the respective distal and proximal ends of the bones and the interosseous ligament. The distal end of the curving radius became drawn down over the end of the curving ulna in a partial overlap position (Figs. 14 and 18). Meanwhile the firmly attached paw, following the changing outline of the leg bones, became directed outwards away from the trunk. In the final and permanent deformity, the bowing of the slender radius in most cases was actually more pronounced than that of the stockier ulna; in both bones the area of greatest curvature was the central and distal segments. Various degrees of flattening and of rotation of these bones also took place.

The bowing deformity increased rapidly, reaching its peak at about 2 months of age or a little later. At this time, as is well shown by serial x-ray photographs, the extensive lesion of the distal epiphysis of the ulna began to regress. This process proceeded rather rapidly, healing was generally well under way at 3 months of age and was complete at about 4 months. The forelegs appeared to be little or not at all shortened, except in those cases in which the bones were very markedly twisted. From numerous x-ray photographs of the skeleton and from postmortem examinations (5) it was found that the distal ulna epiphysis was the only area primarily involved, the other skeletal changes which occurred being secondary or dependent upon the development and course of the ulna lesion.

There appeared to be a direct relationship between the degree of bowing eventually attained and the general physical condition of the growing rabbit. It was noted that if the youngster did not thrive, particularly in the 2nd and 3rd week of life, with consequent retardation of body growth and reduced body weight gains, the progressive course of the ulna lesion tended to be retarded. It was in these cases that prompt fostering often turned the tide; that is, if improvement in general health took place and continued under the new conditions of material care, the progressive course of the lesion was resumed. This relationship was reversed in the case of non-hereditary foreleg bowing, which occasionally developed in poorly nourished cachectic nurslings.

There was no relationship between body size and weight and the grade or severity of the deformity.

Beveren and Belgian rabbits are large, heavy animals while French Silver rabbits are in a medium to large class. The possibility that weight might influence the degree of deformity was considered in connection with the weight-bearing function of the forelegs. However, the deformed hybrid and mongrel stocks which were assembled, contained many small, light animals whose deformities developed at a comparable rate and to the same degree as those of large, heavy individuals. This was also the case in the smaller rabbits of pure Dutch breed in which the hereditary bowing condition was also observed.

The results of blood chemistry determinations expressed as mean weekly values showed that during the first 8 weeks of life, the serum calcium levels of the deformed rabbits were slightly higher than those of the normal rabbits and that thereafter they were slightly lower. With 2 exceptions, at 5 and 6 weeks of age, the serum phosphorus levels of the deformed rabbits were higher than those of the controls. The respective curves representing the values for the $\text{Ca} \times \text{P}$ products (Chart 1) show consistently higher levels for the deformed rabbits. In active rickets, it will be remembered, lower values prevail. The alkaline phosphatase values (Chart 2) of the deformed rabbits during the first 4 weeks of life, that is, during the very active phases of the epiphyseal ulnar lesion, were considerably higher than those of the normal rabbits but after a precipitous drop were somewhat lower.

Treatment of affected nurslings with haliver oil and viosterol, and exposure to direct sunlight were without effect on the development and course of the deformity. The administration of haliver oil and viosterol to the pregnant and nursing doe, as well as fostering with an unrelated doe, also had no effect.

The hereditary character of the foreleg abnormality suggested by the results of the early breeding experiments with the original Beveren stock was later confirmed. It was found that all surviving offspring of deformed parents likewise developed the deformity. In the genetic studies here reported the appearance of F_1 hybrid crosses proved to be normal, and heterozygous transmitters were identified only by test breeding experiments. These several hereditary features in the Beveren stock were also found to be associated with the similar bowing abnormality of the pure Belgian, French Silver, and Dutch stocks. A familial distribution of the deformity characterized all 4 examples. In none of the other Beveren, Belgian, French Silver, and Dutch stocks, of fifteen other pure breeds or in the hybrid and mongrel stocks of the colony, did hereditary foreleg bowing develop.

The period of observation of the rabbit colony referred to in this report was 20 years. During this time the total number of adult rabbits which were followed from birth to adult age was many thousands and an additional very large number were nurslings under observation for a few weeks. In these circumstances it is reasonably certain that only in the particular Beveren, Belgian,

French Silver, and Dutch families did the hereditary bowing deformity occur. However, since the abnormality developed in 4 different pure breeds and in the case of 1 of them, at a time widely separated from that of the others, its actual incidence rate might be higher than the present observations suggest. In this connection it should be remembered that commercial breeders customarily destroy not only ill and poorly nourished individuals but also those which develop untoward or peculiar features, among which bowed legs would almost certainly be included. None of the many rabbits that were purchased from dealers and rabbitries for use in this laboratory before the colony was organized showed leg deformities.

The curious bowing and flipper deformity closely resembles a condition in human beings, in which, however, the radius is primarily affected (9). In Madelung's deformity which is occasionally seen, the forearms are bowed and the hands are displaced ventrally. The main defect is dyschondroplasia of the lower radial epiphysis, the symptoms beginning in adolescence. In the great majority of cases both forearms are affected. There is some evidence of a familial hereditary basis for the condition. Female cases outnumber the male cases in a ratio of approximately 4:1. A case of an unusual type of Madelung-like deformity, in which an ulnar dyschondroplasia occurred, has been reported (10).

SUMMARY

An inwardly directed curvature of the distal segment of both forelegs of the rabbit has been described. The condition was detected at 2 to 3 weeks of age, developed rapidly, and reached its final and permanent stage at 2 to 3 months of age. Only the distal epiphysis of the ulna was primarily affected and this in the form of a massive chondrodystrophic lesion accompanied by a progressive curvature of the shaft. The curvature of the growing radius was a secondary effect due to the firm, immovable, anatomical connection of the ulna and radius. The positional changes of the wrist and paw were likewise effects secondary to the changed form of the ulna and radius.

The bowing abnormality occurred only in certain families of pure bred Beveren, Belgian, French Silver, and Dutch rabbits and was found to be inherited. The mode of inheritance was on the basis of a single recessive unit factor (5).

BIBLIOGRAPHY

1. Brown, W. H., Constitutional variation and susceptibility to disease, *Harvey Lectures*, 1928-29, **24**, 106.
2. Brown, W. H., and Pearce, L., Hereditary achondroplasia in the rabbit. I. Physical appearance and general features, *J. Exp. Med.*, 1945, **82**, 241. Pearce, L., and Brown, W. H., Hereditary achondroplasia in the rabbit. II. Pathologic

- aspects, *J. Exp. Med.*, 1945, **82**, 261. Pearce, L., and Brown, W. H., Hereditary achondroplasia in the rabbit. III. Genetic aspects; general considerations, *J. Exp. Med.*, 1945, **82**, 281.
3. Pearce, L., and Brown, W. H., Hereditary osteopetrosis of the rabbit. I. General features and course of disease; genetic aspects, *J. Exp. Med.*, 1948, **88**, 579. Pearce, L., Hereditary osteopetrosis of the rabbit. II. X-ray, hematologic, and chemical observations, *J. Exp. Med.*, 1948, **88**, 597. Pearce, L., Hereditary osteopetrosis of the rabbit. III. Pathologic observations; skeletal abnormalities, *J. Exp. Med.*, 1950, **92**, 591. Pearce, L., Hereditary osteopetrosis of the rabbit. IV. Pathologic observations; general features, *J. Exp. Med.*, 1950, **92**, 601.
 4. Greene, H. S. N., Oxycephaly and allied conditions in man and in the rabbit, *J. Exp. Med.*, 1933, **57**, 967.
 5. Pearce, L., Hereditary distal foreleg curvature in the rabbit. II. Genetic and pathological aspects, *J. Exp. Med.*, 1960, **111**, 823.
 6. Pearce, L., Constitutional (inherited) rachitic-like disorders in the rabbit, *Arch. Path.*, 1938, **25**, 763.
 7. Bensley, B. A., *Practical Anatomy of the Rabbit*, Toronto, The University of Toronto Press, 1938.
 8. Greene, H. S. N., Rabbit pox. I. Clinical manifestations and course of disease, *J. Exp. Med.*, 1934, **60**, 427.
 9. Anton, J. I., Reitz, G. B., and Spiegel, M. B., Madelung's deformity, *Ann. Surg.*, 1938, **108**, 411.
 10. Wright, L. T., and Kaufman, J., Unusual type of Madelung-like deformity; case presentation, *Am. J. Surg.*, 1936, **34**, 365.
 11. Clark, E. P., and Collip, J. B., A study of the Tisdall method for the determination of blood serum calcium with a suggested modification, *J. Biol. Chem.*, 1925, **63**, 461.
 12. Bodansky, A., Notes on the determination of serum inorganic phosphate and serum phosphatase activity, *J. Biol. Chem.*, 1937, **120**, 167.

EXPLANATION OF PLATES

All illustrations are reproduced from untouched photographs made by Mr. J. A. Carlile.

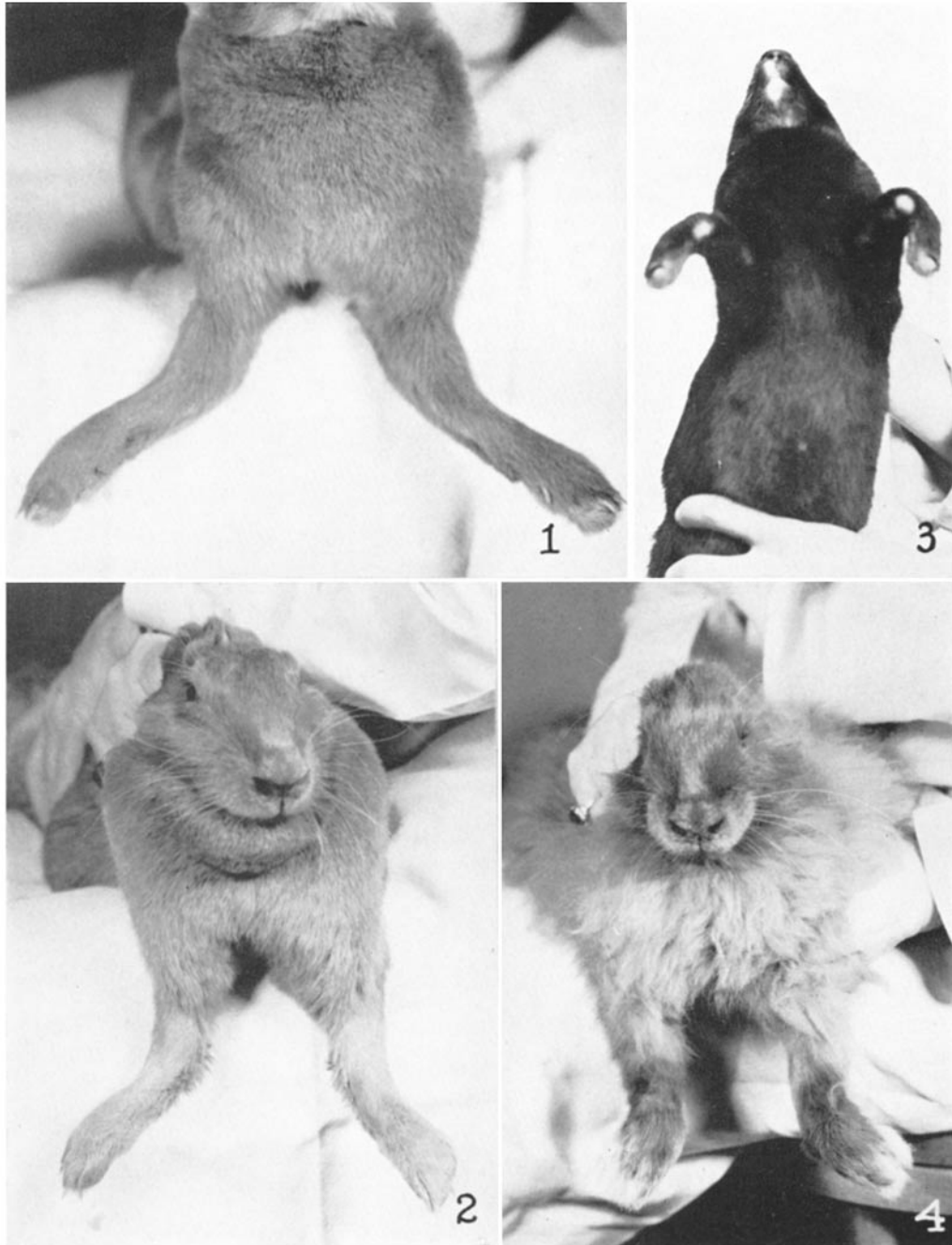
PLATE 68

FIG. 1. The forelegs of a Beveren female rabbit, aged 1 yr. 2 mos., to show the pronounced inward bowing of the distal segments. There was also some twisting of the radius and ulna in a forward and outward direction. The flipper position of the paws is not well shown. An x-ray photograph of a similarly deformed Beveren rabbit of the same age is reproduced in Fig. 27.

FIG. 2. The forelegs of a Beveren female rabbit, 1 yr. old, to show the marked inward bowing of the distal segments. Both paws were held in a flipper position; that of the left paw (to the right) is better shown. The ulna and radius of both legs were flattened anteroposteriorly.

FIG. 3. Photograph of a Dutch hybrid male rabbit, 4 mos. old, with pronounced inward bowing and flipper deformity. Note the denuded cutaneous areas on the medial-posterior surface of both lower forelegs. These were calloused areas in contact with the ground. The ulna and radius of both legs showed marked dishing, flattening, and twisting. An x-ray photograph of the same rabbit at 4 yrs. 10 mos. of age is reproduced in Fig. 29.

FIG. 4. Photograph of the forelegs of a Beveren male angora rabbit, 3 mos. old, to show the flipper paw deformity which was pronounced on the left and moderate on the right. The inward bowing of both forelegs is not well shown. X-ray photographs at 22 and 43 days of age are reproduced in Figs. 10 and 14.



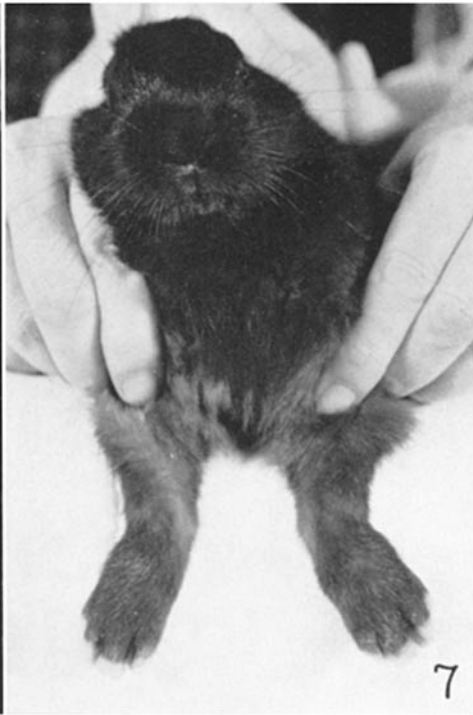
(Pearce: Hereditary distal foreleg curvature. I)

PLATE 69

FIG. 5. Photograph of 2 pure bred Beveren litter mate rabbits, aged 66 days. The rabbit on the left showed well marked foreleg bowing and a slight sprawl. The rabbit on the right was normal. This was a backcross litter and it contained the second examples of the deformity observed in the colony.

FIG. 6. Photograph of an F² hybrid Beveren male rabbit, aged 56 days. The lower forelegs showed well marked inward bowing, and in addition the bones were considerably flattened and twisted.

FIG. 7. Photograph of a nursling Beveren male rabbit, aged 32 days, to show an early stage of bilateral inward bowing and flipper deformity. The deformity was pronounced at 2 mos.



(Pearce: Hereditary distal foreleg curvature. I)

PLATE 70

FIG. 8. X-ray photograph of the left foreleg of a female rabbit, aged 13 days, to show the characteristic early expansion, thickening, and irregularities of the distal epiphysis of the ulna. The distal epiphysis of the radius is possibly somewhat thickened. To be compared with Fig. 9.

FIG. 9. X-ray photograph of the right lower foreleg of a normal rabbit, aged 15 days; for comparison with Fig. 8.

FIG. 10. X-ray photograph of the right foreleg of a 22 day old rabbit with early bowing. Note particularly the very marked irregularity of the expanded distal epiphysis of the ulna. To be compared with Fig. 11. An x-ray photograph of the left foreleg at 43 days of age is depicted in Fig. 14 and a photograph of the rabbit at 3 mos. of age is reproduced in Fig. 4.

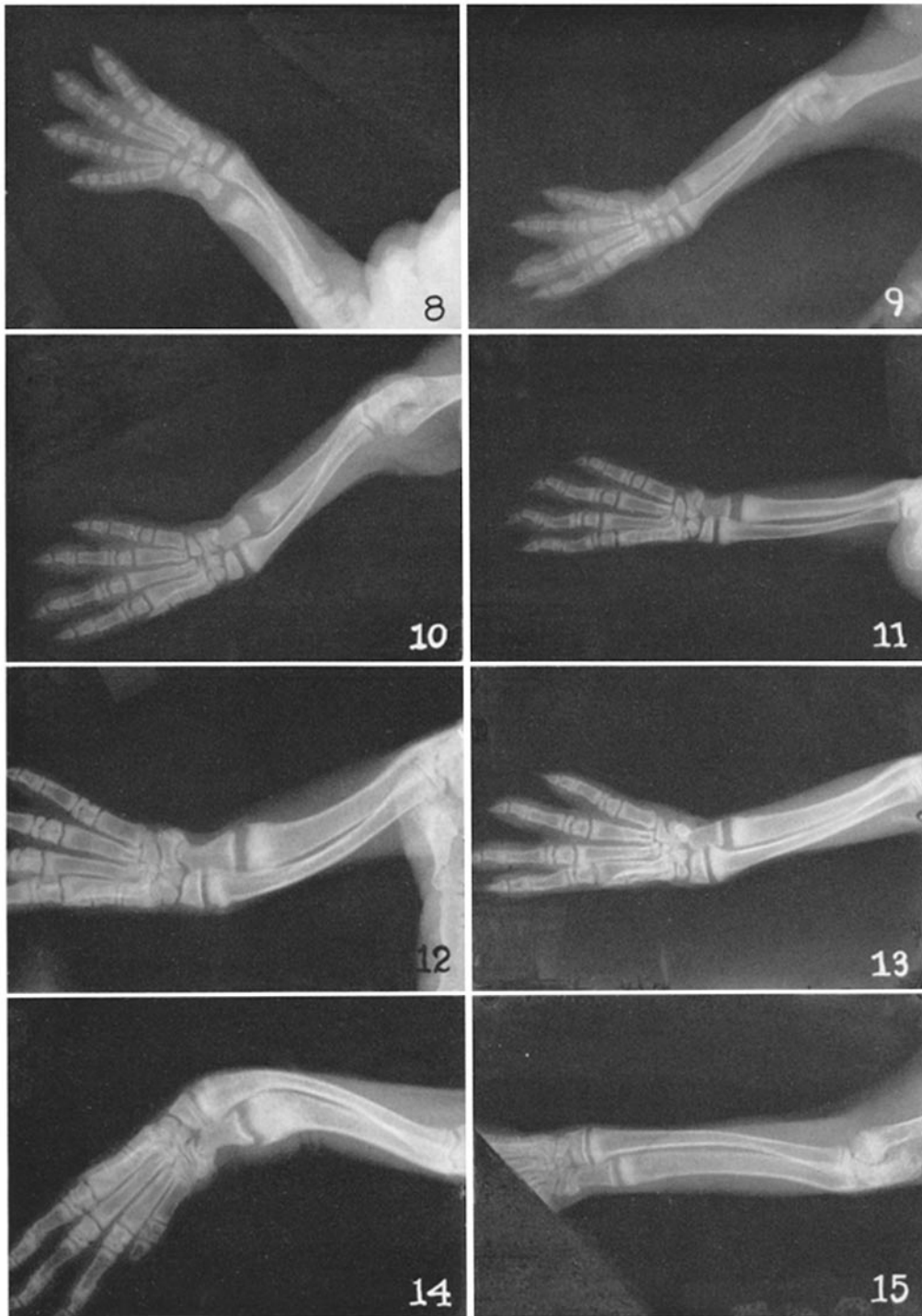
FIG. 11. X-ray photograph of the right lower foreleg of a normal rabbit aged 21 days; for comparison with Fig. 10

FIG. 12. X-ray photograph of the right foreleg of a 32 day old rabbit with inward bowing. The distal ulna epiphysis is greatly expanded and thickened and somewhat irregular. The distal portion of the curved radius is beginning to overlap the ulna epiphysis. To be compared with Fig. 13.

FIG. 13. X-ray photograph of the right lower foreleg of a normal rabbit, aged 32 days; for comparison with Fig. 12.

FIG. 14. X-ray photograph of the left foreleg of a 43 day old rabbit with a pronounced bowing and flipper deformity. A comparable x-ray photograph of a normal rabbit, aged 39 days, is depicted in Fig. 15. The distal epiphysis of the ulna is markedly widened, thickened, and irregular; that of the radius is possibly slightly thickened. This is the same rabbit whose x-ray photograph at 22 days of age is reproduced in Fig. 10 and whose photograph at 3 mos. of age appears in Fig. 4.

FIG. 15. X-ray photograph of the lower left foreleg of a normal rabbit aged 39 days; for comparison with Fig. 14.



(Pearce: Hereditary distal foreleg curvature. I)

PLATE 71

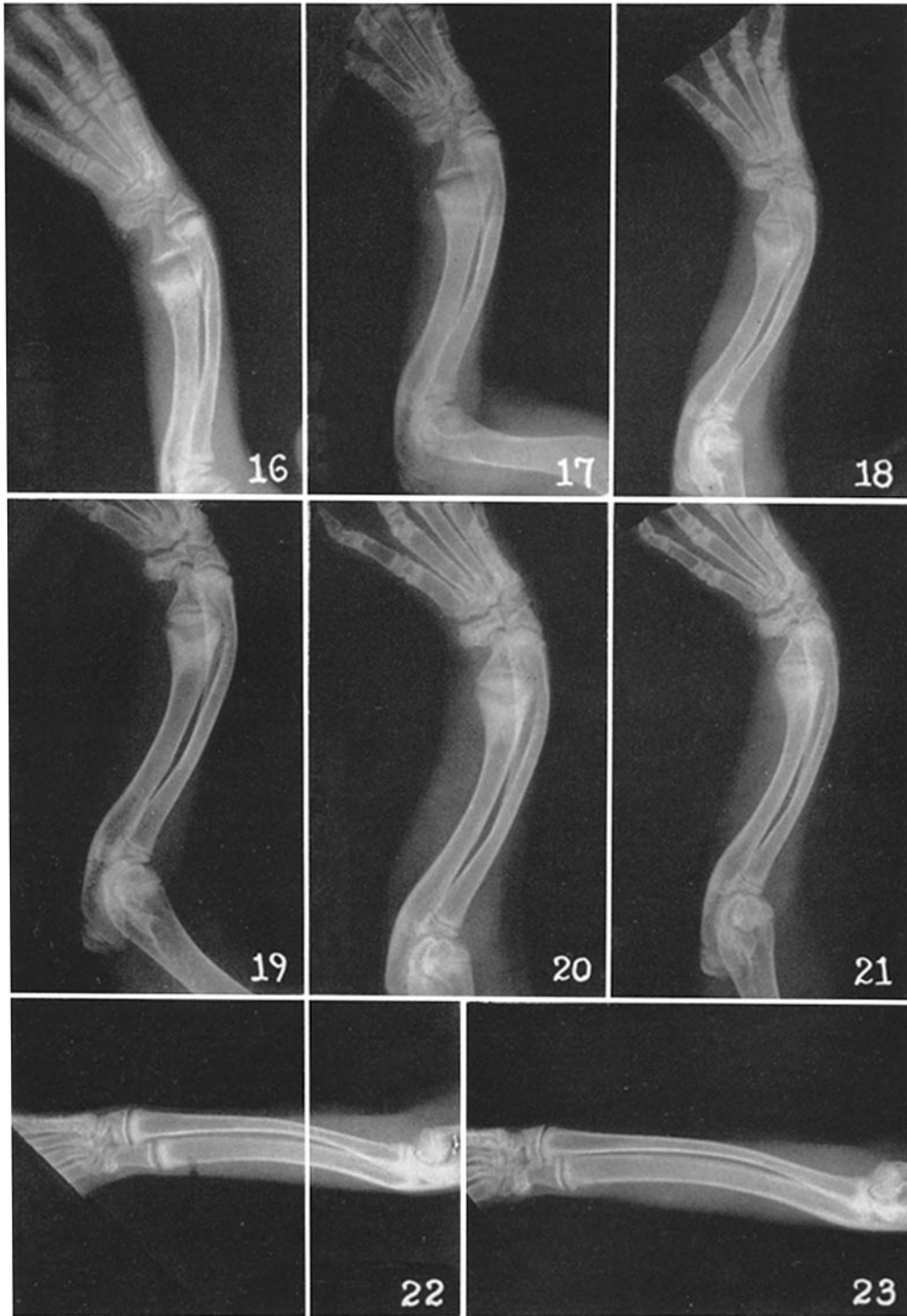An example of the successive changes in the foreleg bones of a deformed rabbit aged 6 weeks to 10 mos. of age is shown in a series of 9 x-ray photographs of the left lower foreleg reproduced in Figs. 16 to 21 and in Figs. 24 to 26.

FIGS. 16, 17, and 18. X-ray photographs of the left foreleg taken at the ages of 41, 48, and 54 days, respectively. The distal epiphysis of the ulna is greatly expanded, thickened, and irregular, and "cupping" is a prominent feature. (The condition was acute and actively progressing.) The distal epiphysis of the radius is possibly slightly thickened. Both bones show inward bowing and the distal portion of the curving radius overlaps the ulna. The position of the paw is directed laterally away from the body. For comparison with the appearance of the normal foreleg bones, an x-ray photograph taken at 51 days is reproduced in Fig. 22.

FIGS. 19, 20, and 21. X-ray photographs of the left foreleg taken at 62, 69, and 77 days of age respectively. The principle differences between these x-ray photographs and the preceding one taken at 54 days of age (Fig. 18) are an increase in the curvature of both ulna and radius, a greater overlap of the radius, and a decrease in the irregularities and cupping of the distal epiphysis of the ulna. For comparison, the x-ray photograph of a normal rabbit, aged 78 days, is reproduced in Fig. 23.

FIG. 22. X-ray photograph of the left lower foreleg of a normal rabbit, aged 51 days.

FIG. 23. X-ray photograph of the left lower foreleg of a normal rabbit, aged 78 days.



(Pearce: Hereditary distal foreleg curvature. I)

PLATE 72

The x-ray photographs reproduced in Figs. 24 to 26 are of the left foreleg of the same rabbit whose earlier x-ray photographs appear in Figs. 16 to 21.

FIG. 24. X-ray photograph taken at 111 days of age. Note the marked curvature of both ulna and radius; the radius overlaps the ulna in the distal third of the bones. The distal ulnar epiphysis shows very little expansion or thickening, and probably no cupping. The articulation of the ulna with the triquetral bone of the carpus shows a dislocation directed laterally and inwardly toward the lunate bone.

FIG. 25. X-ray photograph taken at 5½ mos. of age. The bowing of both radius and ulna is marked and the distal third of the radius continues to overlap the medial edge of the ulna. The dislocated ulna-carpus articulation continues to be marked. The flipper position of the paw is pronounced. The appearance of the distal epiphysis of the ulna is practically normal.

FIG. 26. X-ray photograph taken at 10 mos. of age. The bowing deformity of both leg bones and the distal radial overlap are marked. The paw points acutely outward.

The dislocated ulna-carpus articulation is well shown. For comparison an x-ray photograph of the left foreleg of a normal rabbit, aged 10½ mos. of age, is reproduced in Fig. 29.

FIG. 27. X-ray photograph of the lower forelegs of another deformed rabbit, aged 1 yr. 2 mos., to show the marked degree of permanent bowing and flipper condition.

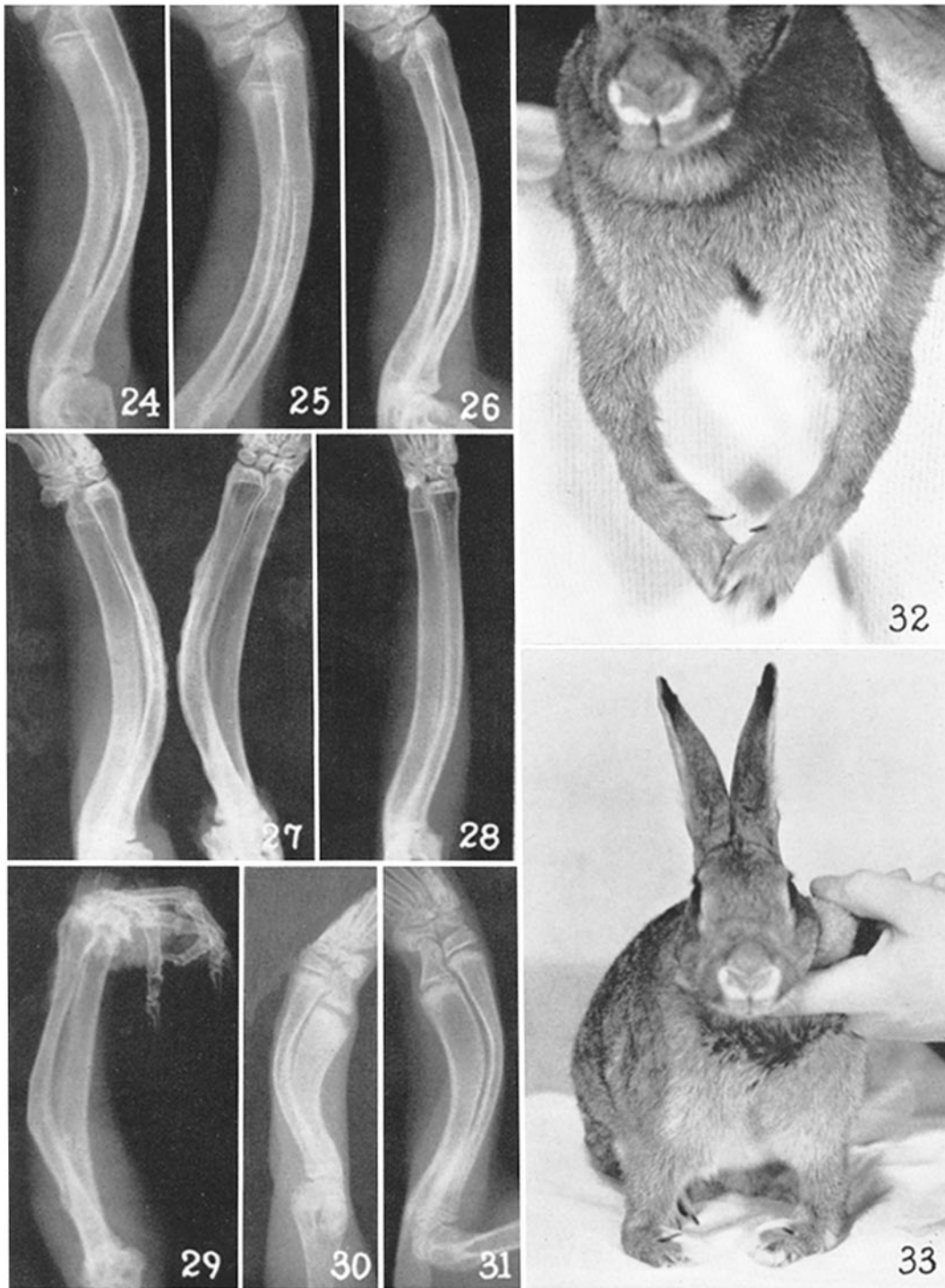
FIG. 28. X-ray photograph of the left foreleg of a normal pure bred Havana rabbit, aged 10½ mos.

FIG. 29. X-ray photograph of the left lower foreleg of a deformed rabbit aged 4 yrs. 10 mos., the same rabbit whose earlier photograph is reproduced in Fig. 3. The permanent bowing deformity is pronounced, and the radial overlap in both distal and proximal areas is considerable. The markedly flexed paw is directed outwardly as is usual.

FIG. 30. X-ray photograph of the right lower foreleg of a 32 day old rabbit with non-hereditary inward bowing of the ulna and radius. The distal epiphysis of the ulna shows moderate expansion and widening and slight irregularities, but no cupping.

FIG. 31. X-ray photograph of the left lower foreleg of a 66 day old rabbit with non-hereditary well marked inward bowing of the ulna and radius. The distal epiphysis of the ulna shows very slight residual thickening.

FIGS. 32 and 33. Photographs of the forelegs of a hybrid mongrel rabbit aged 2 yrs., 8 mos., to show non-hereditary outward bowing of the distal forelegs. The condition was well marked.



(Pearce: Hereditary distal foreleg curvature. I)